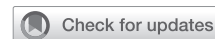

Durability of right ventricular conduits in the Ross procedure



Karen B. Abeln, MD,^a Lennart Froede, MD,^a Christian Giebels, MD,^a and Hans-Joachim Schäfers, MD^{a,b}

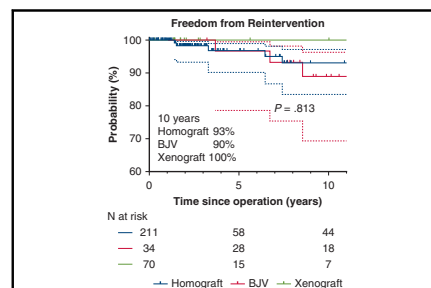
ABSTRACT

Background: Right ventricular (RV) conduit availability and degeneration are potential limitations of the Ross procedure. Pulmonary homografts are the gold standard, but their limited availability drives the need for alternatives. The aim of this study was to compare results of different RV conduits.

Methods: Between 1995 and 2023, 315 consecutive patients (73% males; mean age, 37 ± 12 years) underwent a Ross procedure using a homograft ($n = 211$), bovine jugular vein (BJV) ($n = 34$), or xenograft ($n = 70$) as the RV conduit. The mean follow-up was 5.7 ± 6.7 years and was 96% complete (1631 patient-years).

Results: Twelve patients (homograft, $n = 8$; BJV, $n = 3$; xenograft, $n = 1$) required RV conduit reintervention, including 4 patients within 4 years (all with homografts). Indications for reintervention were degeneration in 8 patients and active endocarditis in 4 patients. Reinterventions included RV conduit replacement (homograft, $n = 3$; xenograft, $n = 1$; BJV, $n = 2$) and transcatheter valve implantation (homograft $n = 5$; BJV, $n = 1$). At 15 years, freedom from RV conduit reintervention was 88%, and freedom from reoperation was 93%. Freedom from reintervention at 15 years was similar in the homograft (89%), BJV (89%), and xenograft (100%) groups ($P = .812$). Progression of mean RV conduit gradient was lowest for the BJV group (1.45 mm Hg/year) and similar in the homograft (2.6 mm Hg/year) and xenograft (2.9 mm Hg/year) groups. Age at <18 years at surgery (hazard ratio [HR], 1.9; $P < .001$) was a predictive risk factor for reintervention. There was no difference among the RV conduit groups (HR, 1.198; $P = .606$).

Conclusions: The incidence of reintervention after 15 years is similar in recipients of homografts, xenografts, and BJV grafts. Interestingly, homografts may fail in the first few years, possibly related to inflammatory phenomena. Thus, the use of xenografts may be an option if homografts are not available. (J Thorac Cardiovasc Surg 2025;169:1306-14)



Freedom from reintervention (95% confidence interval) according to RV conduit type.

CENTRAL MESSAGE

The durability of homografts and xenografts as right ventricular conduits is similar up to 15 years after implantation.

PERSPECTIVE

Pulmonary homografts remain the gold standard as right ventricular conduits in the Ross procedure, but retraction may lead to early reintervention. Up to 15 years postimplantation, the durability of stentless xenografts is similar to that of homografts. Thus, the use of xenografts may be an option for older patients if the availability of homografts is limited; the optimal cutoff remains to be defined.

See Commentary on page 1315.

The Ross procedure has several advantages in younger patients, including near-physiologic hemodynamics, a low incidence of valve-related complications, and survival equivalent to that of an age- and sex-matched population.¹ Despite the recent resurgence of interest in the Ross procedure, its use remains limited.^{2,3} A possible explanation for this is the more complex nature of the procedure compared to conventional valve replacement; another relates to the need for a right

ventricular (RV) conduit. The pulmonary homograft has been the gold standard for this purpose; however, its availability is limited in terms of both sizes and numbers, and the option of a more widely available RV conduit is desirable.

Although homografts are the traditional standard as RV conduits, their durability is not always ideal. A recent study found a relevant incidence of reintervention in the first year after surgery (3.5%/year).⁴ In addition, homografts degenerate

From the ^aDepartment of Cardiovascular Surgery, Saarland University Medical Center and Saarland University, Homburg, Saar, Germany; and ^bDepartment of Thoracic and Cardiovascular Surgery, Westpfalz Hospital, Kaiserslautern, Germany.

Read at the 104th Annual Meeting of The American Association for Thoracic Surgery, Toronto, Ontario, Canada, April 27-30, 2024.

Received for publication March 24, 2024; revisions received Sept 7, 2024; accepted for publication Oct 9, 2024; available ahead of print Oct 22, 2024.

Address for reprints: Karen B. Abeln, MD, Department of Cardiovascular Surgery, Saarland University Medical Center, Kirrbergerstr. 100, 66424 Homburg, Germany (E-mail: karen.abeln@uks.eu). 0022-5223

Copyright © 2024 The Author(s). Published by Elsevier Inc. on behalf of The American Association for Thoracic Surgery. This is an open access article under the CC BY license (<http://creativecommons.org/licenses/by/4.0/>). <https://doi.org/10.1016/j.jtcvs.2024.10.023>

Abbreviations and Acronyms

BJV	= bovine jugular vein
CI	= confidence interval
HR	= hazard ratio
IQR	= interquartile range
RV	= right ventricular
RVOT	= right ventricular outflow tract

To view the AATS Annual Meeting Webcast, see the URL next to the webcast thumbnail.

over time, and RV conduit calcification is the main late complication necessitating reintervention, particularly in younger patients.⁴ The precise mechanism of early or late degeneration is not well known; inflammation and an immune reaction between the host and the homograft may play a role.⁵ The use of decellularized homografts with the aim of reducing inflammation⁶ is not yet supported by long-term data.⁷

The limited availability of homografts has led to a search for alternative grafts.^{8,9} When interpreting results of different studies, one must differentiate between pediatric patients (with expected somatic postoperative growth) and adults. Few studies have investigated the use of porcine stentless aortic prostheses in adults.⁹⁻¹² In 3 studies, the results were generally comparable with those of pulmonary homografts.¹¹⁻¹³ In 1 study, a higher probability of xenograft dysfunction was observed owing to the development of a stricture at the proximal suture line when an autologous pericardial sleeve was interpositioned between the xenograft and the RV outflow tract (RVOT).¹⁰ Interestingly, gradients tended to be somewhat lower with xenograft valves. Bovine jugular vein (BJV) has been used as an alternative RV conduit for the Ross procedure, and is readily available in a wide range of sizes up to 22 mm.

For the Ross procedure, we have followed a policy of obtaining a homograft for elective procedures. If surgery was urgent and a homograft was not available, we resorted to an alternative conduit. Over time, we were positively impressed by the low incidence of degeneration with the alternative conduits.

The aim of this study was to review our long-term experience with different RV conduits (pulmonary homograft, stentless xenograft, BJV) in the Ross procedure. Primary endpoints were survival and freedom from reintervention; secondary endpoints were predictors for conduit dysfunction and progression of degeneration.

METHODS

This study was approved by the Saarland Regional Ethics Committee (CEP 203/19; approved May 15, 2018). Individual patient consent was waived for the analysis and publication in an anonymized fashion.

Patients

We conducted a retrospective analysis of patients who underwent a Ross procedure at Saarland University Medical Center between December 1995 and August 2023. The use of stentless xenografts as RV conduits was introduced in 1998 for adult patients without an available homograft, and they have been used for patients age >40 years and for elective procedures since 2020. The use of BJVs was introduced in 2002.

The patients were analyzed according to RV conduit type (homograft, BJV, or xenograft). Survival, freedom from reoperation, and mean RV conduit gradient were compared across the 3 groups. In a further analysis, adult patients were compared with pediatric patients.

Criteria for RV Conduit Reintervention

In patients with RV enlargement or systolic dysfunction, with or without pulmonary regurgitation and RV systolic pressure >35 to 40 mm Hg, right cardiac catheterization was performed to quantify and verify RV conduit dysfunction (relevant regurgitation and/or mean gradient ≥ 30 mm Hg and signs of RV load). If a diagnosis of dysfunction was confirmed, patients underwent RV conduit reintervention.

Surgical Technique

The full-root replacement technique was performed in all but 5 cases. Technical details have been described previously, using the remnants of the native aortic root as autologous autograft support in the majority of patients.¹⁴ The pulmonary valve was replaced with a cryopreserved pulmonary homograft, a BJV (Contegra; Medtronic), or a xenograft (Freestyle SX; Medtronic). For size determination, body surface area was taken into account; however, the largest available conduit was systematically used for the xenograft and homograft, to mitigate the hemodynamic impact of homograft stenosis.

All conduits were implanted in anatomic orientation with continuous sutures at the proximal and distal ends using 4-0 polypropylene. No material was included in the suture on the RVOT. The coronary ostia were placed anteriorly so that they were easily accessible for hemostasis.

Follow-up

All patients were seen regularly by their referring cardiologist or in our clinic. Echocardiograms from our institution and from referring cardiologists were reviewed. All patients were followed prospectively both clinically and echocardiographically at discharge, 3 months, 1 year, and yearly thereafter. Mean gradients were measured using continuous-wave Doppler. Pulmonary regurgitation was determined using color Doppler according to European guidelines.

The median and mean duration of follow-up were 3.6 (IQR, 2-10) years and 5.6 ± 6.7 years overall. By group, follow-up was 5.2 (IQR, 0.1-9) years and 6.2 ± 4.1 years in the homograft group, 3.1 (IQR, 1-7) years and 3.7 ± 4.8 years in the stentless xenograft group, and 11 (IQR, 9-15) years and 12 ± 4 years in the BJV group. Follow-up was 96% complete (1631 patient-years).

Statistical Analysis

Non-normally distributed continuous variables are presented as median (interquartile range [IQR]), and continuous variables are presented as mean \pm standard deviation. They were compared using analysis of variance with post hoc tests and Bonferroni correction for normally distributed data and the Kruskal-Wallis test for non-normally distributed data. Categorical variables are expressed as frequency (%). Time-dependent data were analyzed using the Kaplan-Meier method. Differences were assessed using the log-rank test. Survival and freedom from reintervention were calculated at 1, 5, 10, and 15 years. All statistical tests were 2-sided, and a *P* value < .05 was considered statistically significant for all analyses. Patients were censored either at last follow-up or at death.

Cox proportional hazard regression was performed to identify predictors for reintervention and death. In logistic regression analysis, variables during univariable analysis were chosen based on clinical relevance for entry into the multivariable analysis. All models were adjusted for patient age, sex, and relevant comorbidities coded as yes/no.

Changes in mean gradients were evaluated using a spline regression model with repeated measurements and residuals clustered on the patient level. All model iterations included age, sex, and type of RV conduit as control variables. Overall, 400 gradient measurements were included with a minimum number of gradients per patient of 2 and a maximum of 10. The visualization was performed using the R *ggplot* package.

Statistical analyses were performed using SPSS Statistics for Macintosh, version 28.0 (IBM) and R version 4.4.0 (R Foundation for Statistical Computing).

RESULTS

Patients

The cohort comprised 315 consecutive patients, 73% male, with a mean age of 37 ± 12 years. RV conduits were created with a homograft in 211 patients (67%), BJV in 34 patients (11%), and a xenograft in 70 (22%) (Table 1, Figure 1). Twenty-four patients (8%) were age <18 years; of these, 18 had a homograft, 4 had a BJV graft, and 2 had a xenograft. The 291 adult patients included 193 with a homograft, 30 with a BJV graft, and 68 with a xenograft. In 36 patients (11%), active endocarditis was the indication for surgery. Overall, 256 cases (81%) were elective, 54 cases (17%) were urgent, and 5 cases (2%) were emergency procedures.

Patients who received a xenograft were older than patients with a homograft or a BJV graft (mean, 44 ± 11 years vs 35 ± 12 years vs 35 ± 9 years; $P < .001$). The median conduit diameter was 27 mm (homografts, 27 mm; xenografts, 29 mm; BJV grafts, 22 mm) (Table 2).

Early

There were no cases of myocardial infarction and only 1 neurologic complication. The patient had a right coronary artery anomaly and developed RV dysfunction that was treated by coronary artery bypass and an RV assist device (for 5 days). He experienced a thromboembolic stroke but completely recovered neurologically and has been well since. Another patient required a temporary left ventricular assist device for ventricular dysfunction. She was weaned successfully on postoperative day 5 and continues to do well. There was no significant difference among the treatment groups in terms of perioperative complications (Table 2).

There were 2 early deaths (1 each in the homograft group and xenograft group). One patient underwent surgery following 3 previous root replacements and died from uncontrollable hemorrhage due to autograft rupture after 2 weeks. The second patient had reduced left ventricular function preoperatively; he developed low cardiac output postoperatively with severe nonocclusive mesenteric ischemia and died from multiorgan failure at postoperative day 5.

TABLE 1. Baseline characteristics

Characteristic	BJV (N = 34)	Homograft (N = 211)	Xenograft (N = 70)	P value
Male sex, n (%)	29 (85)	148 (70)	45 (70)	.681
Age, y, mean \pm SD	35 ± 9	35 ± 12	44 ± 11	<.001
BSA, m ² , mean \pm SD	1.2 ± 0.2	1.7 ± 0.6	1.9 ± 0.9	<.001
Cardiovascular risk factors, n (%)				
Arterial hypertension	14 (41)	60 (29)	24 (38)	.402
Coronary artery disease	0 (0)	3 (2)	3 (5)	.163
Intravenous drug abuse	2 (6)	7 (4)	1 (2)	.622
Surgical indication, n (%)				
Isolated aortic regurgitation	9 (26)	39 (18)	13 (19)	.011
Isolated aortic stenosis	5 (16)	62 (29)	21 (30)	.055
Combined disease	9 (26)	90 (43)	31 (44)	.065
Endocarditis	11 (32)	20 (10)	5 (7)	<.001
Prior cardiac procedure, n (%)	16 (47)	68 (32)	13 (20)	.244
Valve morphology, n (%)				
Unicuspid	10 (29)	106 (50)	35 (55)	.071
Bicuspid	13 (38)	76 (36)	25 (39)	.851
Tricuspid	9 (26)	28 (13)	4 (6)	.067
LVEF <50%, n (%)	0 (0)	22 (10)	4 (6)	.026
LVEDd, mm, mean \pm SD, mm	57 ± 13	55 ± 11	62 ± 8	.073

Bold type indicates statistical significance. BJV, Bovine jugular vein; SD, standard deviation; BSA, body surface area; LVEF, left ventricular ejection fraction; LVEDd, left ventricular diastolic diameter.

TABLE 2. Perioperative data

Variable	BJV (N = 34)	Homograft (N = 211)	Xenograft (N = 70)	P value
Full root replacement, n (%)	34 (100)	205 (97)	70 (100)	—
RV conduit size, median, mm (IQR)	20 (18-22)	27 (26-29)	29 (28-30)	.062
Concomitant procedure, n (%)	9 (28)	25 (12)	6 (9)	.101
Ascending aortic replacement	6 (19)	48 (23)	31 (44)	<.001
Septal myectomy	2 (6)	9 (4)	3 (4)	.631
Hemi-arch using circulatory arrest	2 (6)	5 (3)	3 (4)	.234
Rescue coronary artery bypass	2 (6)	2 (1)	1 (2)	.711
Tricuspid valve repair	1 (3)	2 (1)	1 (2)	.898
Mitral valve repair	1 (3)	3 (2)	1 (2)	.802
Myocardial ischemia, min, mean \pm SD	93 \pm 14	90 \pm 20	92 \pm 21	.531
Perfusion time, min, mean \pm SD min	131 \pm 30	122 \pm 32	127 \pm 37	.795
Perioperative complications, n (%)				
Myocardial infarction	0 (0)	0 (0)	0 (0)	—
Stroke	0 (0)	0 (0)	1 (1)	—
Ventricular dysfunction necessitating VAD	1 (1)	1 (1)	0 (0)	.887

Bold type indicates statistical significance. BJV, Bovine jugular vein; RV, right ventricular; IQR, interquartile range; SD, standard deviation; VAD, ventricular assist device.

Late

Endocarditis. Four patients (1.3%) were diagnosed with isolated RV conduit endocarditis (at a mean of 6.2 ± 3.4 years postoperation). All patients were age <18 years at the time of the Ross procedure. Of these, 2 patients had a BJV graft, 1 patient had a homograft, and 1 patient had a xenograft as their RV conduit. The risk of RV conduit endocarditis was 0.25% per patient-year.

Survival. Ten patients (3%) died during follow-up (homograft group, n = 7; xenograft group, n = 1; BJV group, n = 2), including 4 of cardiac causes (8 months to 4 years postoperation). The cardiac causes included RV conduit endocarditis (due to continued intravenous drug abuse; n = 1), cardiac arrhythmia (n = 2), and uncontrollable coagulopathy (presumed heparin-induced thrombocytopenia; n = 1). Five patients died from noncardiac causes (6 months

TABLE 3. Postoperative RV conduit hemodynamics

Variable	Pulmonary regurgitation, grade >2/n	Mean gradient, mm Hg, \pm SD	Peak gradient, mm Hg, \pm SD
Discharge TTE			
Xenograft	0	8 \pm 2	12 \pm 5
Homograft	0	3 \pm 4	8 \pm 3
Bovine jugular vein	0	5 \pm 5	9 \pm 4
P value	N/A	.077	.081
TTE 1 y postoperatively			
Xenograft	0	10 \pm 3	18 \pm 6
Homograft	1	5 \pm 5	14 \pm 3
Bovine jugular vein	0	7 \pm 5	16 \pm 4
P value	N/A	.062	.331
TTE 5 y postoperatively			
Xenograft	0	12 \pm 3	21 \pm 5
Homograft	3	8 \pm 3	17 \pm 4
Bovine jugular vein	0	10 \pm 6	20 \pm 4
P value	N/A	.072	.561
Last follow-up TTE			
Xenograft	0	14 \pm 5	24 \pm 12
Homograft	3	11 \pm 9	22 \pm 16
Bovine jugular vein	0	13 \pm 12	25 \pm 17
P value	N/A	.658	.883

SD, Standard deviation; TTE, transthoracic echocardiography; N/A, not applicable; RV, right ventricular.

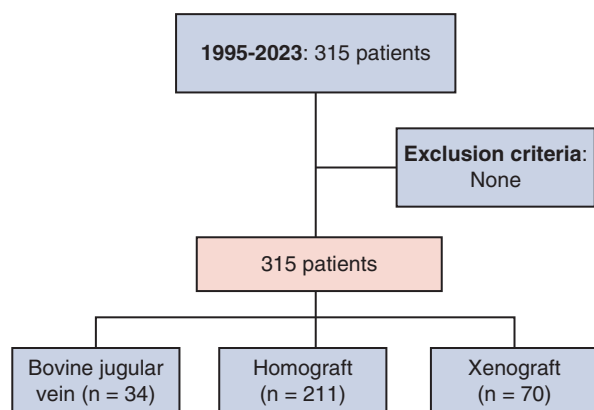


FIGURE 1. Flow chart of the study population.

to 11 years postoperation); causes of death were sepsis from urinary tract infection (n = 1), pneumonia (n = 1), intravenous drug abuse (n = 1), and oropharyngeal cancer (n = 1) and unknown (n = 1).

Overall survival was 91% at 15 years, and freedom from cardiac death was 96%. At 10 years, survival was similar in the homograft (94%), BJV (94%), and xenograft (98%) groups ($P = .689$) (Figure 2).

By Cox regression analysis, active endocarditis at the time of the Ross procedure was associated with increased mortality (hazard ratio [HR], 2.86; 95% confidence interval [CI], 0.61-13.36; $P = .037$), whereas the use of external autograft support was associated with increased survival (HR, 0.27; 95% CI, 0.08-0.95; $P = .038$). The type of RV conduit was not associated with mortality (HR, 1.176; 95% CI, 0.676-2.048; $P = .566$).

RV Conduit Reintervention

Twelve patients (4%) underwent 15 RV conduit reintervention (homograft group, n = 7; BJV group, n = 4; xenograft group, n = 1) at a median of 7.4 years (IQR, 4.3-9.2 years) postoperatively (homograft group, 1-19 years; BJV group, 4-9 years). The patient with a xenograft underwent reintervention at age 18 years. Indications for reintervention were RV conduit stenosis (n = 6, 50%; homograft group, n = 4; BJV group, n = 1; xenograft group, n = 1), combined disease (homograft group, n = 2; 17%), and active endocarditis (n = 4, 33%; homograft group, n = 1; BJV group, n = 2; xenograft group, n = 1).

Freedom from any RV conduit reintervention at 15 years was 88% overall and similar in the homograft (89%), BJV (89%), and xenograft (100%) groups ($P = .812$) (Figure 3). It was higher in adult patients compared to pediatric patients (96% vs 55%; $P < .001$) (Figure 3, B). At 10 years, freedom from reintervention in adults was lowest in the BJV group compared to the homograft and xenograft groups (89% vs 99% vs 100%; $P = .156$) (Figure 3, C). In pediatric patients, freedom from reintervention at 5 years was similar

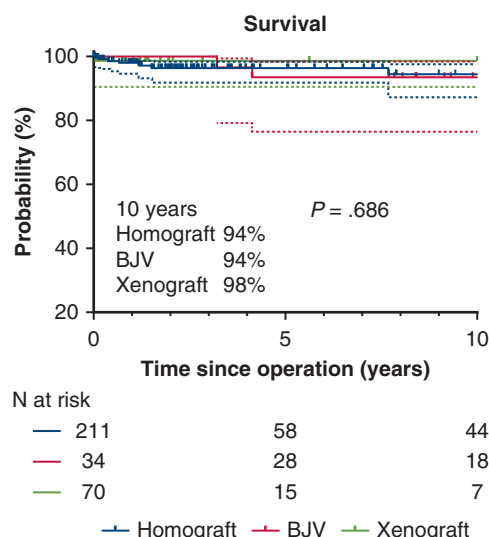


FIGURE 2. Survival (95% confidence interval) of patients according to RV conduit type. BJV, Bovine jugular vein.

in the BJV and homograft groups (83% vs 75%; $P = .697$) (Figure 3, D).

Freedom from RV conduit reoperation was 93% at 15 years overall and was comparable in the homograft, BJV, and xenograft groups (95% vs 92% vs 100%; $P = .631$). It was higher in adult patients (97%) compared to pediatric patients (97% vs 67%; $P = .003$).

Reinterventions included surgical RV procedures, including conduit replacement (n = 7, 67%; homograft, n = 3; BJV, n = 3; xenograft, n = 1), conduit repair with a patch plasty (n = 1), and transcatheter valve implantation (n = 4, 33%; homograft, n = 3; BJV, n = 1).

Among the 12 patients requiring reinterventions, 2 were pediatric patients who underwent a reoperation, with a subsequent need for transcatheter valve implantation. The first patient (age 3) initially had a xenograft, which degenerated by 1 year postoperation. The conduit was replaced with a BJV, which became stenotic after 16 years and required reintervention with a transcatheter valve. After 5 months, the transcatheter valve degenerated and was replaced with a homograft. The second patient (age 9 years) initially had a homograft, which became stenotic 7 years postoperation and required replacement with another homograft. That homograft became stenotic again 4 years postoperatively and required transcatheter valve implantation.

One patient developed homograft degeneration by 1.5 years postoperation. At reoperation, the conduit was enlarged by a patch plasty. Because of a postoperative increase in gradients, he was treated by steroids for 12 months, and has been reintervention-free for 6 years. He was later diagnosed with autoimmune arteritis.

By Cox regression analysis, freedom from reintervention did not differ among the 3 study groups (HR, 1.198; 95% CI, 0.708-2.57; $P = .606$). The probability of reintervention

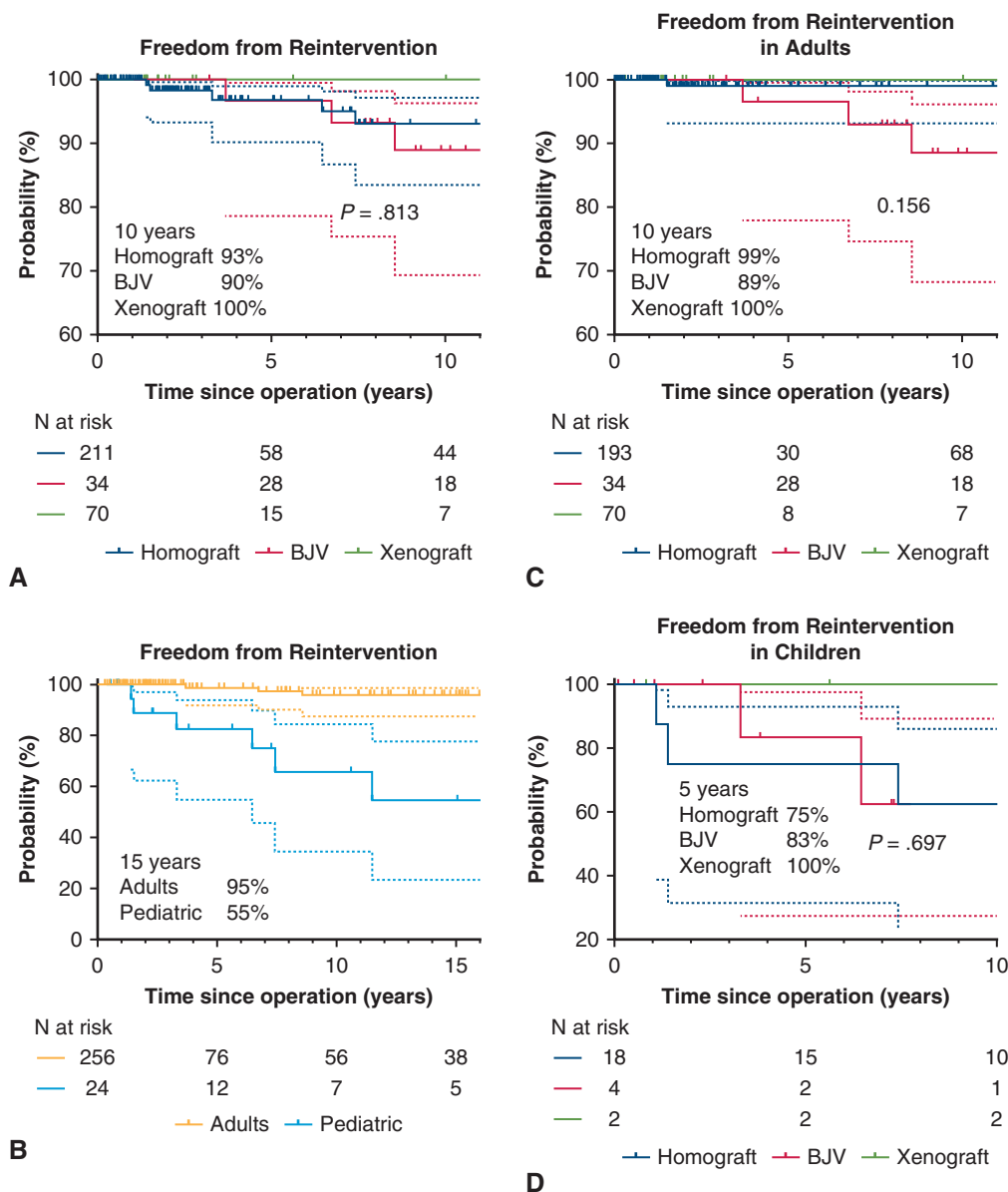


FIGURE 3. A, Freedom from reintervention (95% confidence interval) according to RV conduit type. B, Freedom from reintervention in adult versus pediatric patients. C, Freedom from reintervention in adult patients according to RV conduit type. D, Freedom from reintervention in pediatric patients according to RV conduit type. BJV, Bovine jugular vein.

was higher in pediatric patients (age <18 years) (HR, 0.91; 95% CI, 0.87-0.95; $P < .001$). Larger conduit size showed a trend toward an association with reduced rate of reintervention, although this not achieve the predefined criteria for statistical significance (HR, 0.53; 95% CI, 0.26-1.062; $P = .073$).

Gradients. The progression of mean pulmonary gradients was greatest in the first 5 postoperative years. During this period, the increase was 1.52 mm Hg/year in the BJV group ($P = .005$), 2.4 mm Hg/year in the homograft group ($P = .003$), and xenografts showed an increase of 2.8 mm Hg/year in the xenograft group ($P = .003$). Between 5

and 10 years, progression rates were lower in the homograft group (0.78 mm Hg/year; $P = .020$) and the BJV group (0.36 mm Hg/year; $P = .39$) compared to the xenograft group (1.6 mm Hg/year; $P = .04$) (Figure 4). Postoperative hemodynamics are displayed in Table 3.

All the patients who developed early degeneration (within the first 4 years) without the need for reoperation were pediatric patients or young adults.

DISCUSSION

During the initial Ross procedure, aortic homografts were used as RV conduits.⁸ Later, pulmonary homografts

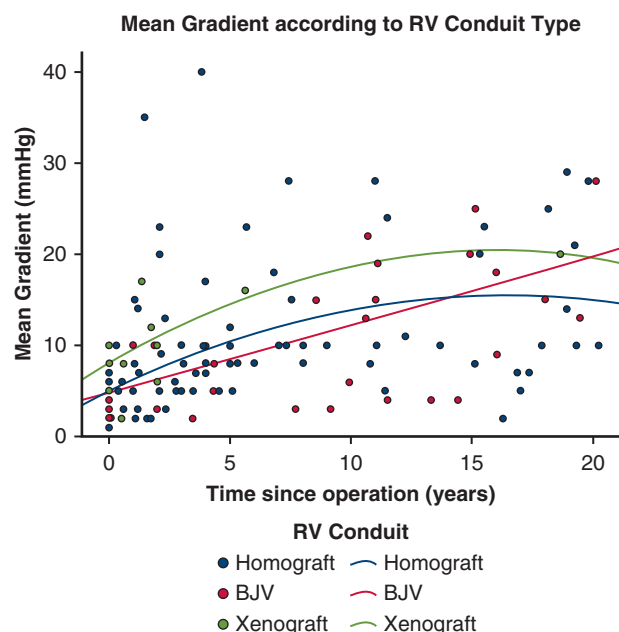


FIGURE 4. Progression of mean gradients over time. BJV, Bovine jugular vein.

were introduced, and their superior results compared with aortic homografts made them the gold standard for this procedure.¹⁵ However, the shortage of suitable homografts and limited availability in some countries stimulated the search for alternative RV conduits. Moreover, pulmonary homografts are not free from degeneration.

The mechanism of homograft degeneration likely involves immune reactions from the host.⁵ Both the pulmonary valve and trunk are involved, and we have observed shrinkage of the implanted pulmonary trunk tissue as early as the first postoperative year. These structural changes occur more frequently and earlier in younger patients.⁴ Shrinkage may explain why degeneration becomes a problem earlier in smaller conduits compared to “oversized” conduits.⁹ In our study, some younger patients experienced relevant homograft stenosis within the first 4 postoperative years, and a more predominant degenerative progress was seen during the first 5 years. We did not observe a relationship between conduit size and earlier degeneration, most likely due to our policy to always attempt “oversizing.” To reduce the immunologic response, decellularized homografts have been used, with promising early results.¹⁶ Apparently, these grafts are not completely free from an immune response, which has been found to be stronger in younger patients.⁷ This currently unresolved issue challenges the homograft as a “gold” standard. The evidence for a positive effect of immunosuppressive therapy remains very weak.¹⁷

Stentless xenografts have been suggested as alternative RV conduits. They are attractive because of their wide

availability and long-term success in the aortic position; in fact, in one study, its performance was identical to that of an aortic homograft.¹⁸ Some studies in pediatric patients have shown comparable results for stentless xenografts and pulmonary homografts,^{9,13,19} and others have even shown superior durability of stentless xenografts.²⁰ Several investigations have analyzed their use in the Ross procedure in adults,¹⁰⁻¹² and 2 of these included small cohorts with xenografts.^{11,12} Nevertheless, these reports showed similar degeneration over time for homografts and stentless xenografts. Only 1 study reported a problem with the proximal suture line between xenograft and RVOT; the authors had added a sleeve of pericardial tissue between the right ventricle and the xenograft.¹⁰ While our follow-up remains limited, the use of xenografts appears to be a reasonable alternative to homografts, at least in older individuals.

In our study, freedom from reintervention was similar for the homograft group and the xenograft group. We did not observe any early xenograft reintervention, and only 1 patient required reoperation 18 years postoperatively. Although the pulmonary homografts exhibited lower transvalvular gradients compared to xenografts, they had a similar progression as xenografts. This is in line with previous findings from an animal study in which homograft, xenograft, and BJV cusps were unaffected by the degeneration process, with degeneration observed mostly along the conduit wall.²¹

The BJV has been used mostly in pediatric patients because of the smaller conduit sizes. Studies have shown that, depending on the conduit size, between 70% and 90% of patients are reintervention-free after 10 years.^{22,23} BJV grafts have been reported to perform just as well as or even better than pulmonary homografts,^{22,24-26} similar to our findings in pediatric patients. These positive results may be explained by the BJV’s tendency to dilate over time,²⁷ which may partially accompany the somatic growth of children and allows for a somewhat longer freedom from reoperation. However, concerns have been expressed over increased rates of late endocarditis.²⁸⁻³⁰ In addition, inflammatory stenosis at the distal pulmonary anastomosis with fibrointimal proliferation have been observed, particularly in smaller conduits.^{28,31} These findings were made in pediatric patients; we have made similar observations during correction of conotruncal anomalies.

Less is known on the long-term fate of BJV grafts in adults, especially in the Ross procedure. We did not observe any inflammatory shrinkage or distal anastomotic stenosis. At reintervention, the BJV was found to be 1.3 to 1.5 times larger than at the time of implantation.²⁷ Overall, freedom from reintervention was lower in BJV grafts compared to homografts and xenografts in adults but similar to homografts in pediatric patients. Interestingly, transvalvular gradients were lower in BJV grafts compared to homografts and xenografts. The incidence of late endocarditis was

acceptable ($n = 2$; 5%); only 1 patient required early transcatheter valve implantation (3.4 years postoperation) after healed endocarditis. Thus, the BJV graft appears to be a reasonable option in adults; unfortunately, its availability in larger sizes is limited.

Limitations

The main limitation of this study is its observational design and limited follow-up. Although data of consecutive procedures were obtained prospectively, the analysis was performed retrospectively, and treatment allocation was not randomized. Despite these limitations, this study is one of few mid-term studies comparing the results of different RV conduits in the Ross procedure.

CONCLUSIONS

Survival after the Ross procedure is excellent irrespective of the RV conduit. The use of homografts is associated with a low incidence of dysfunction and reintervention, but degeneration may occur in the first postoperative years. This may be related to inflammatory changes, which we could ameliorate by anti-inflammatory treatment in individual cases. Younger age is an independent risk factor for RV conduit reintervention, whereas larger conduit size shows a trend toward a greater freedom from reintervention. In conclusion, the use of stentless xenografts is an option in adults, and the use of BJV grafts in pediatric patients if homograft availability is limited.

Webcast

You can watch a Webcast of this AATS meeting presentation by going to: <https://www.aats.org/resources/durability-of-rv-conduits-in-t-7287>.



Conflict of Interest Statement

The authors reported no conflicts of interest.

The *Journal* policy requires editors and reviewers to disclose conflicts of interest and to decline handling or reviewing manuscripts for which they may have a conflict of interest. The editors and reviewers of this article have no conflicts of interest.

References

- Mazine A, El-Hamamsy I, Verma S, et al. Ross procedure in adults for cardiologists and cardiac surgeons. JACC State of the Art Review. *J Am Coll Cardiol*. 2018;72(22):2761-2777.
- Yacoub MH, El-Hamamsy I, Sievers HH, et al. Under-use of the Ross operation—a lost opportunity. *Lancet*. 2014;384(9943):559-560.
- Carrel T. The Ross procedure is under-used although long-term results show superior results to those obtained following mechanical aortic valve replacement. *Ann Transl Med*. 2016;4(Suppl 1):S21.
- Chauvette V, Bouhout I, Tarabzoni M, et al. Pulmonary homograft dysfunction after the Ross procedure using decellularized homografts—a multicenter study. *J Thorac Cardiovasc Surg*. 2022;163(4):1296-1305.e3.
- Carr-White GS, Kilner PJ, Hon JK, et al. Incidence, location, pathology, and significance of pulmonary homograft stenosis after the Ross operation. *Circulation*. 2001;104(12 Suppl 1):I16-I20.
- Ghoneim A, Bouhout I, Losenno K, et al. Expanding eligibility for the Ross procedure: a reasonable proposition? *Can J Cardiol*. 2018;34(6):759-765.
- Bobylev D, Horke A, Boethig D, et al. 5-Year results from the prospective European multi-centre study on decellularized homografts for pulmonary valve replacement ESPOIR Trial and ESPOIR Registry data. *Eur J Cardiothorac Surg*. 2022;62(5):ezac219.
- Ross DN. Options for right ventricular outflow tract reconstruction. *J Card Surg*. 1998;13(3):186-189.
- Marathe SP, Bell D, Betts K, et al. Homografts versus stentless bioprosthetic valves in the pulmonary position: a multicentre propensity-matched comparison in patients younger than 20 years. *Eur J Cardiothorac Surg*. 2019;56(2):377-384.
- Miskovic A, Monsefi N, Doss M, Özarslan F, Karimian A, Moritz A. Comparison between homografts and Freestyle® bioprosthesis for right ventricular outflow tract replacement in Ross procedures. *Eur J Cardiothorac Surg*. 2012;42(6):927-933.
- Schmid FX, Keyser A, Wiesenack C, Holmer S, Birnbaum DE. Stentless xenografts and homografts for right ventricular outflow tract reconstruction during the Ross operation. *Ann Thorac Surg*. 2002;74(3):684-688.
- Hechadi J, Gerber BL, Coche E, et al. Stentless xenografts as an alternative to pulmonary homografts in the Ross operation. *Eur J Cardiothorac Surg*. 2013;44(1):e32-e39.
- Dunne B, Suthers E, Xiao P, Xiao J, Litton E, Andrews D. Medium-term outcomes after pulmonary valve replacement with the Freestyle valve for congenital heart disease: a case series. *Eur J Cardiothorac Surg*. 2016;49(5):e105-e111.
- Matsushima S, Abeln KB, Karlíova I, Zacek P, Schäfers HJ. Suture annuloplasty and simplified root wrapping in the full root Ross operation. *Ann Thorac Surg*. 2019;107(5):e361-e363.
- Bando K, Danielson GK, Schaff HV, Mair DD, Julsrud PR, Puga FJ. Outcome of pulmonary and aortic homografts for right ventricular outflow tract reconstruction. *J Thorac Cardiovasc Surg*. 1995;109(3):509-517; discussion 517-518.
- Marathe SP, Hussein N, Wallace FRO, et al. Comparison of homografts and bovine jugular vein conduits in the pulmonary position in patients <20 years of age. *J Thorac Cardiovasc Surg*. 2022;164(3):752-762.e8.
- Al-Jazairi A, Alkotas D, Bulbul Z, Al-Zubairy S, Al-Shahid M, Al-Halees Z. Exploring the role of cyclosporine in reducing homograft degeneration post-Ross. *Asian Cardiovasc Thorac Ann*. 2010;18(6):563-568.
- Melina G, De Robertis F, Gaer JA, et al. Long-term survival after xenograft versus homograft aortic root replacement: results from a prospective randomized trial. *J Thorac Cardiovasc Surg*. 2021;161(1):57-65.
- Novick WM, Anic D, Lora Solf A, et al. Medtronic Freestyle valve for right ventricular reconstruction in pediatric Ross operations. *Ann Thorac Surg*. 2004;77(5):1711-1716.
- Dearani JA, Danielson GK, Puga FJ, et al. Late follow-up of 1095 patients undergoing operation for complex congenital heart disease utilizing pulmonary ventricle to pulmonary artery conduits. *Ann Thorac Surg*. 2003;75(2):399-410; discussion 410-411.
- Flameng W, Jashari R, De Visscher G, Mesure L, Meuris B. Calcification of allograft and stentless xenograft valves for right ventricular outflow tract reconstruction: an experimental study in adolescent sheep. *J Thorac Cardiovasc Surg*. 2011;141(6):1513-1521.
- Fiore AC, Brown JW, Turrentine MW, et al. A bovine jugular vein conduit: a ten-year bi-institutional experience. *Ann Thorac Surg*. 2011;92(1):183-190; discussion 190-192.
- Prior N, Alphonso N, Arnold P, et al. Bovine jugular vein valved conduit: up to 10 years follow-up. *J Thorac Cardiovasc Surg*. 2011;141(4):983-987.
- Boethig D, Schreiber C, Hazekamp M, et al. Risk factors for distal Contegra stenosis: results of a prospective European multicentre study. *Thorac Cardiovasc Surg*. 2012;60(3):195-204.
- Dave H, Mueggler O, Comber M, et al. Risk factor analysis of 170 single-institutional Contegra implantations in pulmonary position. *Ann Thorac Surg*. 2011;91(1):195-302; discussion 202-203.

26. Falchetti A, Demanet H, Dessy H, Melot C, Pierrakos C, Wauthy P. Contegra versus pulmonary homograft for right ventricular outflow tract reconstruction in newborns. *Cardiol Young*. 2019;29(4):505-510.
27. Boudjemline Y, Bonnet D, Massih TA, et al. Use of bovine jugular vein to reconstruct the right ventricular outflow tract: early results. *J Thorac Cardiovasc Surg*. 2003;126(2):490-497.
28. Göber V, Berdat P, Pavlovic M, Pfammatter J-P, Carrel TP. Adverse mid-term outcome following RVOT reconstruction using the Contegra valved bovine jugular vein. *Ann Thorac Surg*. 2005;79(2):625-631.
29. Beckerman Z, De León LE, Zea-Vera R, Mery CM, Fraser CD Jr. High incidence of late infective endocarditis in bovine jugular vein valved conduits. *J Thorac Cardiovasc Surg*. 2018;156(2):728-734.e2.
30. Stammnitz C, Huscher D, Bauer UMM, et al. Nationwide registry-based analysis of infective endocarditis risk after pulmonary valve replacement. *J Am Heart Assoc*. 2022;11(5):e022231.
31. Shebani SO, McGuirk S, Baghai M, et al. Right ventricular outflow tract reconstruction using Contegra valved conduit: natural history and conduit performance under pressure. *Eur J Cardiothorac Surg*. 2006;29(3):397-405.

Key Words: Ross procedure, right ventricular conduit, homograft