


SURGICAL TECHNIQUE

Autologous Transplantation of Press-fit Bone Cylinders in the Treatment of Pelvic Nonunion

Steven C Herath, MD , Benedikt J Braun, MD, Mika F Rollmann, MD, Philipp Mörsdorf, MD, Jörg H Holstein, MD, Tim Pohlemann, MD

Department of Trauma, Hand and Reconstructive Surgery, Saarland University, Homburg, Germany

The present study describes method for autologous bone transplantation to an area of nonunion at the pelvic ring in a way that ensures the best possible bone-to-bone interface (“press-fit”) and provides optimal preconditions for the ingrowth of the bone graft. We modified a technique that has been used to transplant press-fit bone-baseplate-cartilage cylinders for the repair of joint cartilage defects. The technique allows for precise harvesting of bone cylinders with a diamond-coated and fluid-cooled instrument. At the site where the graft shall be inserted, a cylindrical hole is created with a corresponding hollow diamond-coated trephine. This ensures an optimal press-fit implantation of the graft. The new surgical technique has been applied in four patients with nonunion of the pelvic ring. No intraoperative or postoperative complications occurred. In three patients, the procedure led to a reduction of pain and a higher level of mobility as well as a timely radiographic union (imaging not available for another patient). Our technique offers a valuable new treatment option for pelvic nonunion. The current article serves as a proof of concept. Future comparative studies will have to determine its value in detail.

Key words: Bone graft; Nonunion; Pelvic ring fracture; Press-fit cylinder; Treatment

Introduction

Pelvic ring fractures are relatively rare injuries accounting for 2%–8% of all fractures^{1–3}. In younger patients, fractures of the pelvic ring are mostly caused by high-energy trauma, such as falls from greater height or traffic accidents^{3,4}. Among those patients, the rate of pelvic fractures rises to approximately 25%, often associated with multiple injuries^{3,5,6}. In elderly patients, pelvic ring fractures are often caused by low-energy trauma^{7,8}. The incidence of pelvic ring fractures in geriatric patients has been continuously increasing over the last 30 years^{8–11}.

The most acute threat to a patient with a pelvic ring fracture is the severe bleeding that can occur after disruption of the pelvic ring⁴. However, even after successful emergency management of pelvic ring fractures, severe long-term complications may ensue. Nonunion or malunion of the pelvic ring has been reported to occur in up to 5% of all cases of pelvic ring fractures, regardless of the initial treatment¹².

Overall, symptomatic pelvic nonunions and malunions are an even rarer occurrence^{13–15}. Just as for the treatment of acute pelvic ring fractures, the management of pelvic nonunions and malunions is very challenging to the attending surgeon. Different approaches and procedures have been described to facilitate surgical treatment of these complications^{16,17}.

When treating nonunions or malunions, it is of highest importance to achieve sufficient stability, allowing for proper bone healing. Besides that, certain biological preconditions, such as sufficient blood supply and tight-fitting bony contact area, are important for successful treatment of nonunions. Furthermore, debridement of the nonhealing tissue in the former fracture gap is necessary. After debridement, the resulting gap is most commonly filled with autologous bone grafts that can, for example, be harvested from the iliac crest. However, it can be difficult to implant the bone grafts in a

Address for correspondence Steven C. Herath, MD, Department of Trauma, Hand and Reconstructive Surgery, Saarland University, D-66421 Homburg/Saar, Germany Tel: +49-6841-16-31502; Fax: +49-6841-16-31503; Email: steven.herath@uks.eu

Disclosure: All authors declare that there is no conflict of interest, including specific financial interests, relationships, and affiliations relevant to the subject of the manuscript. The project received no specific grant from any funding agency in the public, commercial, or not-for-profit sectors.

Received 3 April 2018; accepted 25 June 2018



manner that provides a tight fit at the site where the graft is needed.

In the treatment of articular cartilage defects, there have been numerous attempts to regenerate or repair damaged cartilage. Because the long-term results of biotechnically engineered cartilage did not meet clinical expectations, more traditional techniques of cartilage transplantation have been moving into focus again^{18–20}. Draenert *et al.* introduced a diamond cutting system to facilitate autologous transplantation of press-fit bone-baseplate-cartilage cylinders^{21,22}. With the use of the so-called Surgical Diamond Instrument (SDI), direct bone healing with a rapid ingrowth of the graft could be observed in line with a good revascularization²¹. Over the years, several studies have shown promising results concerning the ingrowth of press-fit cylinders transplanted using the SDI-technique^{19,23–25}.

While originally the SDI-technique was developed to treat cartilage defects by autologous transplantation of bone-baseplate-cartilage cylinders, we aimed to use the technique to achieve a tight fit of a transplanted bone graft in the treatment of pelvic nonunions, and to create press-fit cylinders serving as an “osteochonductive wick” bridging an area of nonunion.

The purpose of the present study was, therefore, to: (i) implement a method of press-fit bone graft transplantation in nonunions of the pelvic ring; (ii) investigate the clinical and radiographic results; and (iii) discuss the outcome in the context of current literature.

Methods

Technique

In principal, our technique followed the original procedure described by Draenert *et al.*^{21,22}. The Surgical Diamond Instrument system (Karl Storz, Tuttlingen, Germany) allows for precise cutting and harvesting of bone with a diamond-coated and fluid-cooled instrument, which is operated at 800 to 1000 rpm (Fig. 1)²¹. At the site where the graft shall be inserted, a cylindrical hole is created with a hollow diamond-coated trephine, which is available in diameters




Fig. 1 The Surgical Diamond Instrument, a diamond-coated and liquid-cooled trephine available in different diameters and lengths²¹.

from 3.6 mm to 21.1 mm and in two different lengths. Afterwards, a cylindrical graft is harvested from a donor site using a second, corresponding trephine providing a 0.1 mm to 0.15 mm oversize allowing for a press-fit implantation.

While in its original purpose the first trephine is used to excise the cartilaginous defect and the second harvests a bone-baseplate-cartilage graft from the non-weight-bearing area of the knee joint, we used the first instrument to cylindrically excise the nonunion (Figs 2A and 3A) and then harvested a corresponding bone-only graft with the oversized instrument from the iliac crest or the femoral condyle (Figs. 2B and 3B). To estimate the appropriate size of the cylinder, multiplanar CT scans were used for preoperative planning. In our cases, cylinders from 8.5 mm to 12.85 mm in diameter were applied. After harvesting, the graft was inserted at the recipient-site hole using a proprietary pusher (Fig. 2C). The defect at the donor-site was filled by commercially available calcium phosphate cylinders (Synthacer, boneArtis AG, Munich, Germany).

Pitfalls

Depending on the location of the nonunion, it can be difficult to determine the correct orientation and depth of the first trephine when excising a cylinder from the area of nonunion. We found it helpful to insert a guide wire under fluoroscopic control prior to cutting with the SDI-instrument (Fig. 2A). Furthermore, the position and orientation of the first trephine should repeatedly be controlled fluoroscopically in umpteen planes while excising the cylinder.

Especially when operating on the posterior pelvic ring, it is not always possible to locate the exact position of the bone graft with fluoroscopy while inserting the cylinder with a pusher. Therefore, we found it very helpful to mark the far end of the graft cylinder with the tip of a titanium K-wire, which can easily be seen under image intensification. With this simple trick it is possible to ensure that the graft has been pushed in far enough to bridge the nonunion (Fig. 4).

Clinical Cases

From 2014 to 2017, we used the modified SDI-technique in four cases of pelvic nonunions. All patients gave written consent to the procedure itself and the use of their anonymized data for scientific purposes.

Case 1

The first patient was a 28-year-old woman who had sustained multiple injuries in a fall from the second floor of a building. Six months after trauma, she suffered from severe pain of the posterior pelvic ring after nonoperative treatment of a C-type pelvic fracture. Imaging showed a nonunion of a transforaminal fracture of the sacrum without a relevant dislocation and a nonunion of the pubis (Fig. 5).

After placement of a guide wire in the same fashion used for iliosacral screw fixation through the S₁ corridor, a cylinder of 10-mm diameter was extracted crossing the nonunion at the level of the first sacral vertebral body. A corresponding, oversized cylinder was then harvested from the ipsilateral iliac crest

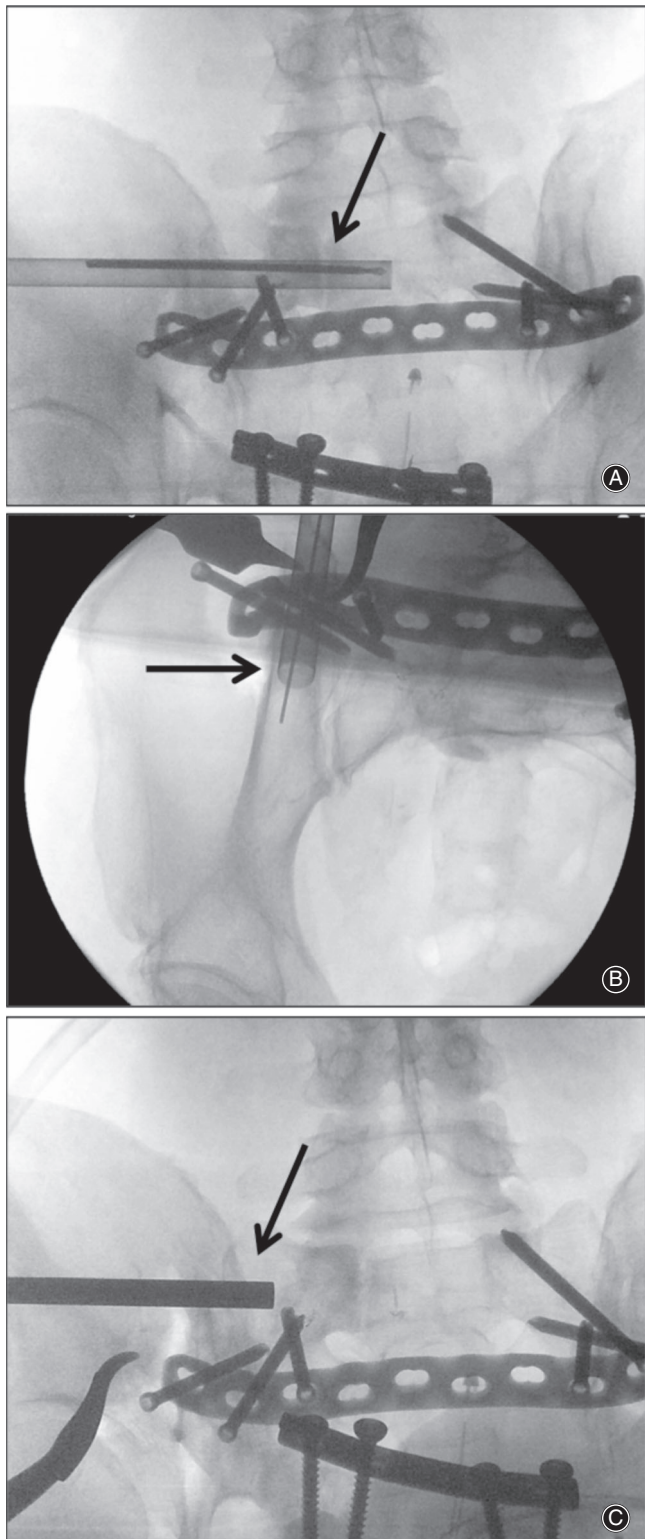


Fig. 2 The modified SDI-technique. (A) A cylinder is excised from the area of the nonunion (arrow) using the first trephine, which can be inserted over a guide wire. (B) A cancellous bone cylinder is harvested with the corresponding, oversized trephine (arrow) from the iliac crest. (C) The graft cylinder is inserted into the prepared canal using a pusher (arrow).

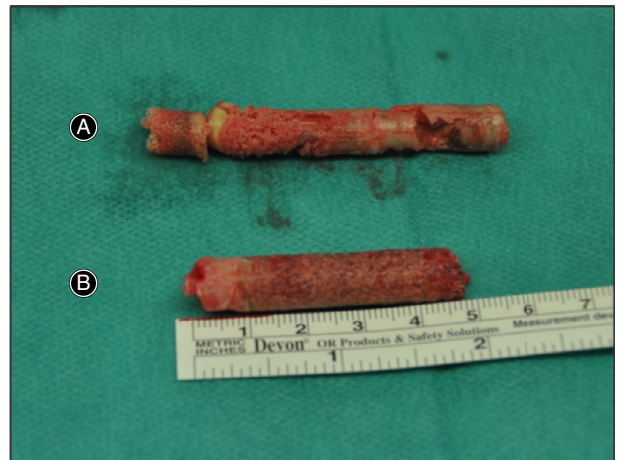


Fig. 3 (A) Cylinder excised from the area of nonunion. (B) The corresponding cancellous bone cylinder that was harvested from the iliac crest.

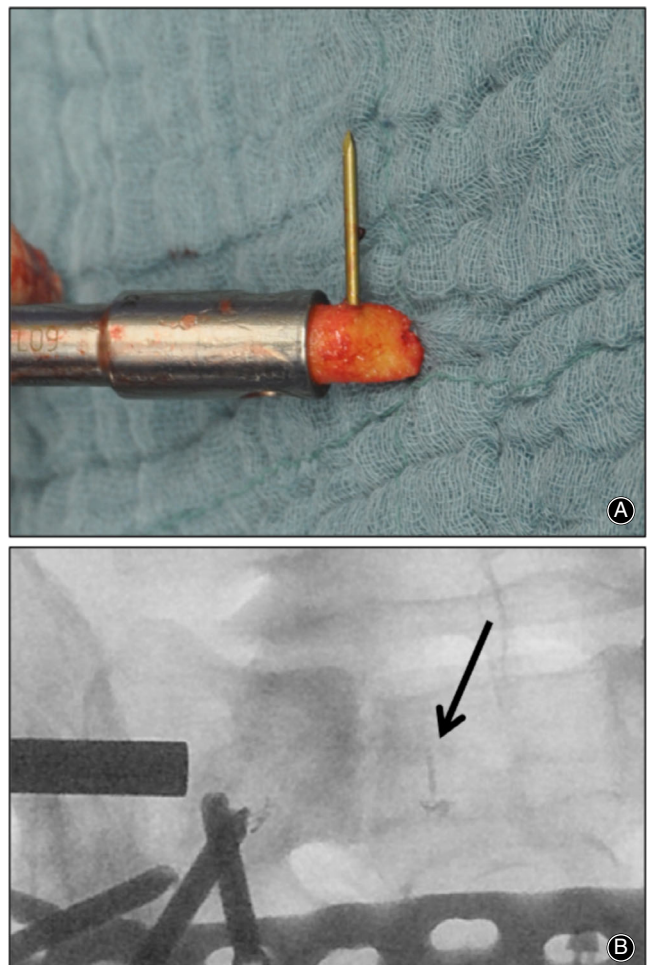


Fig. 4 (A) A titanium K-wire is inserted into the far end of the graft and cut to length so that no metal protrudes from the bone. (B) The titanium-marked end of the graft can be identified under image intensification to verify the correct positioning of the graft.

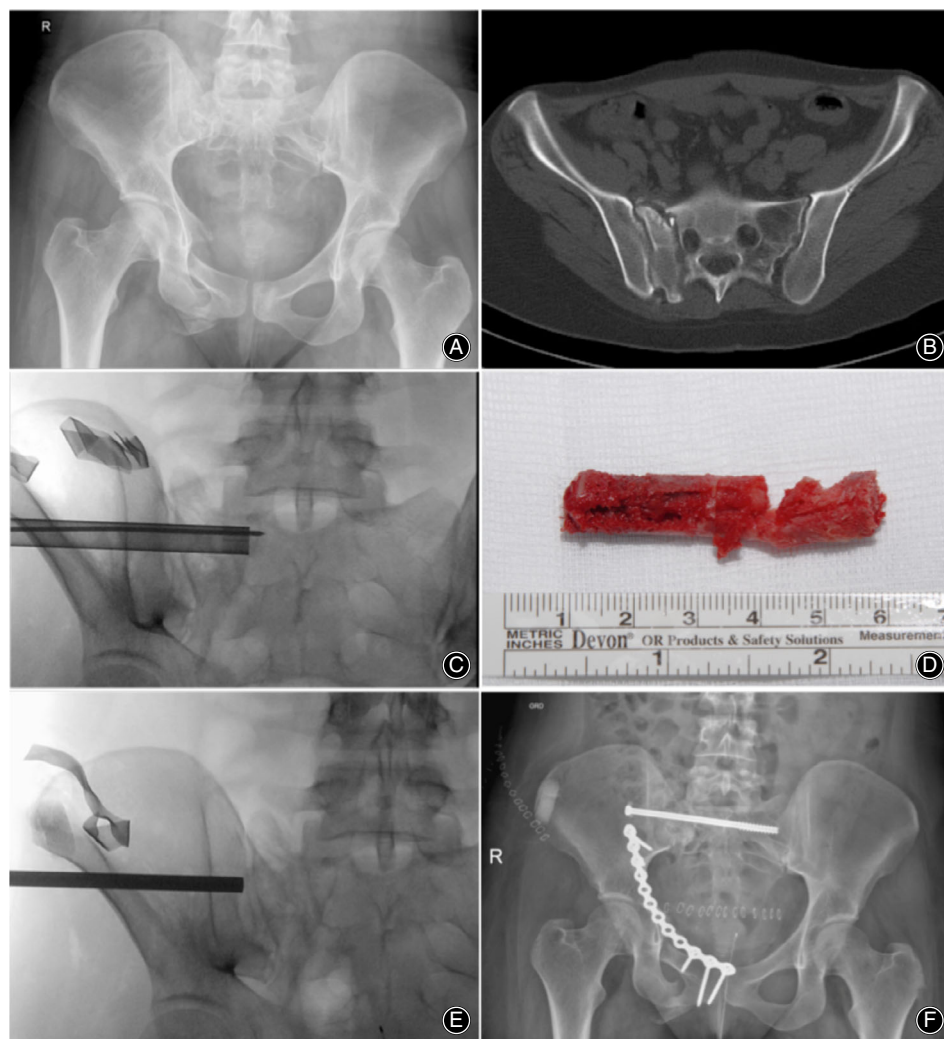


Fig. 5 Nonunion of the anterior (A) and posterior (B) pelvic ring 6 months after trauma. With the modified SDI-technique, a cylinder was harvested from the area of nonunion (C, D) and a bone graft from the iliac crest was inserted (E). An iliosacral screw and an anterior plate were inserted to stabilize the nonunions (F).

and inserted into the prepared canal using the pusher. For additional stability, an iliosacral screw was inserted. After filling the defects at the iliac crest with calcium phosphate cylinders, the anterior nonunion was addressed *via* a Stoppa approach, debrided, and stabilized with a plate.

Case 2

In 2015, a 55-year-old man presented to our department with a painful nonunion of the sacrum after a C-type fracture of the pelvic ring. The patient had already undergone a surgical revision because of the symptomatic nonunion at an external hospital. However, bone healing was not achieved (Fig. 6)

With the patient in prone position, an iliosacral screw was removed and a guide wire was inserted into the existing canal. A cylinder crossing the nonunion was then extracted with the SDI-Instrument. The appropriate oversized cancellous bone cylinder was harvested from the posterior portion of the iliac crest and inserted into the prepared canal to bridge the area of nonunion. For additional stability, two plates were placed on the sacrum *via* a midline dorsal approach. In

addition, cancellous bone from the iliac crest was placed into the area of the nonunion *via* the dorsal approach.

Case 3

In 2016, we used the modified SDI-technique for the treatment of a nonunion of the ilium. A 42-year-old woman presented to our department 18 months after a periacetabular osteotomy for the treatment of hip dysplasia. She suffered from persistent pain due to a nonunion of the periacetabular osteotomy of the ilium (Fig. 7).

The nonunion was approached *via* the same approach that had initially been used for the osteotomy. For better access, we performed an osteotomy of the superior (SIAS) and inferior (SIAI) anterior iliac spine. Then, two cylindrical holes crossing the nonunion were created with the SDI-Instrument. After harvesting two oversized bone cylinders from the ipsilateral iliac crest, they were pushed into the prepared canals. Increased mechanical stability was noted immediately after this procedure. For additional stability, two reconstruction plates were placed on the os ilium before

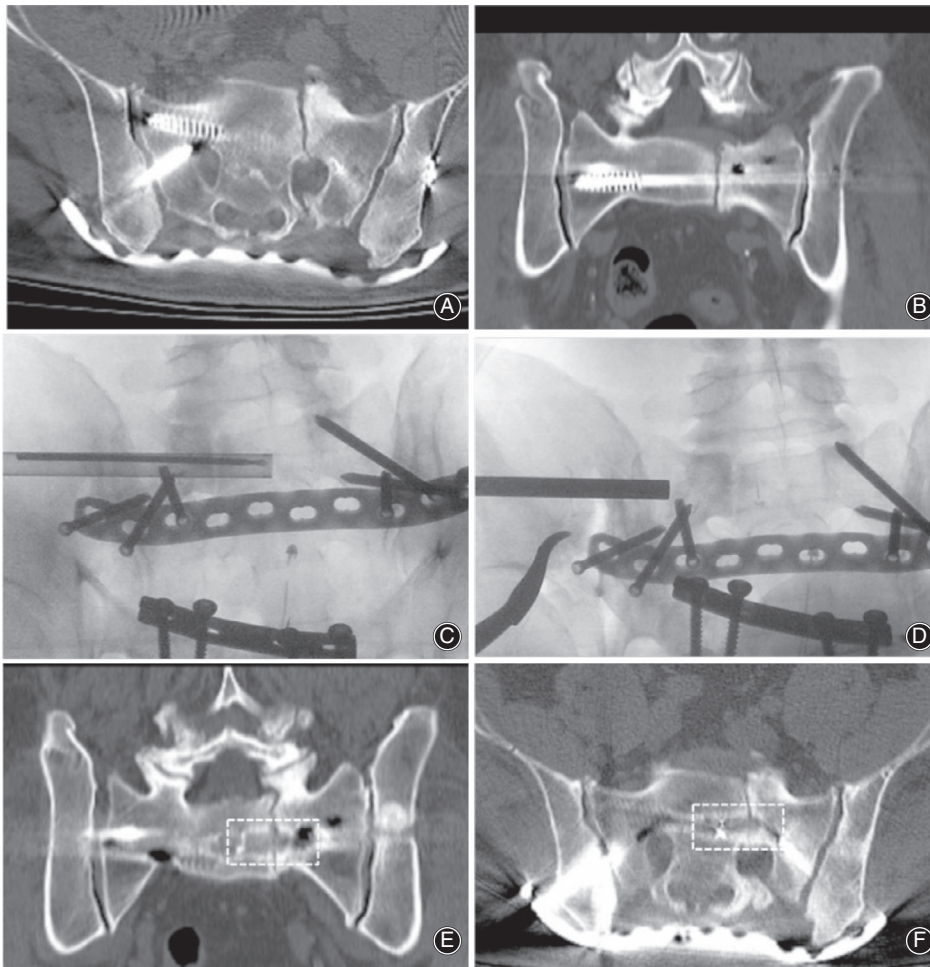


Fig. 6 Nonunion of the sacrum after iliosacral screw stabilization and revision with plate osteosynthesis (A, B). Autologous transplantation of a cylindrical bone graft using the modified SDI-technique (C, D). One year after surgery, the graft had been integrated and the patient's level of pain was reduced (E, F).

the SIAS and SIAI were refixed *via* screw osteosynthesis. Furthermore, a plate was placed on the iliac crest to prevent a stress fracture.

Case 4

The latest case in which we used the new technique was a 55-year-old man. A motorcycle accident had led to a C-type pelvic fracture with disruption of the symphysis and a sacral fracture. Approximately 9 months after the accident, there was a persistent wide dehiscence of the symphysis and a nonunion of the sacrum when the patient first presented to our department. Furthermore, the patient needed a suprapubic urinary catheter because of a complicated rupture of the urinary bladder. The patient was only able to walk short distances using crutches (Fig. 8).

After stabilization of the anterior pelvic ring and preparation of the urinary bladder for later reconstruction, a plate osteosynthesis of the sacrum was performed. After a complicated postoperative course with deep infection at the anterior pelvic ring, we found that even after 6 months the nonunion of the sacrum was not healed. Therefore, we transplanted autologous bone cylinders using the modified SDI-technique. *Via* the approach for iliosacral screw fixation, a cylinder was

excised from the area of nonunion in the sacrum. Because of past multiple harvesting of bone grafts from the iliac crests, we decided to harvest a graft from the nonarticular portion of the right lateral femur condyle. The graft was inserted into the canal using a pusher to bridge the nonunion. The defect at the donor site was filled with calcium phosphate cylinders.

Results

In all cases, the technical procedure was carried out as planned preoperatively without intraoperative complications. All patients could be discharged from the hospital after an uncomplicated postoperative course. No infections at the donor or recipient site occurred. There were no neurological deficits postoperatively. Neither secondary dislocations nor resorption of the press-fit bone grafts were observed.

Case 1

The patient reported as case 1 had been transferred to our hospital from a city approximately 400 km away and, therefore, has not visited our outpatient department again. In a phone interview 4 years after surgery, she reported a complete relief of pain (numeric analogue scale 0). The patient stated that she was able to work full time as a nurse.

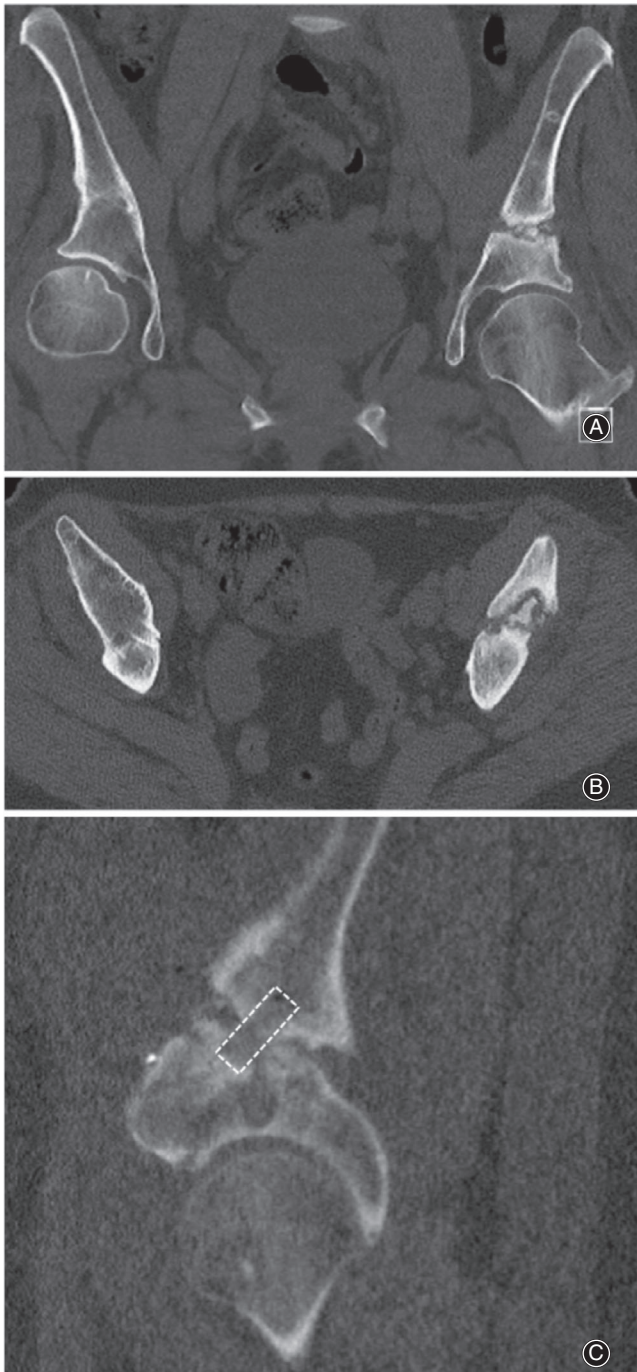


Fig. 7 Nonunion of a periacetabular osteotomy (A, B) in a 42-year-old woman. (C) Postoperative computed tomography of the cylindrical bone graft (dashed line) bridging the nonunion.

Case 2

In one patient (case 2), the follow-up imaging after 12 months showed a good ingrowth of the graft with additional partial bony bridging of the surrounding nonunion area. The patient was able to walk using crutches and reported a significant reduction of pain (numeric analogue

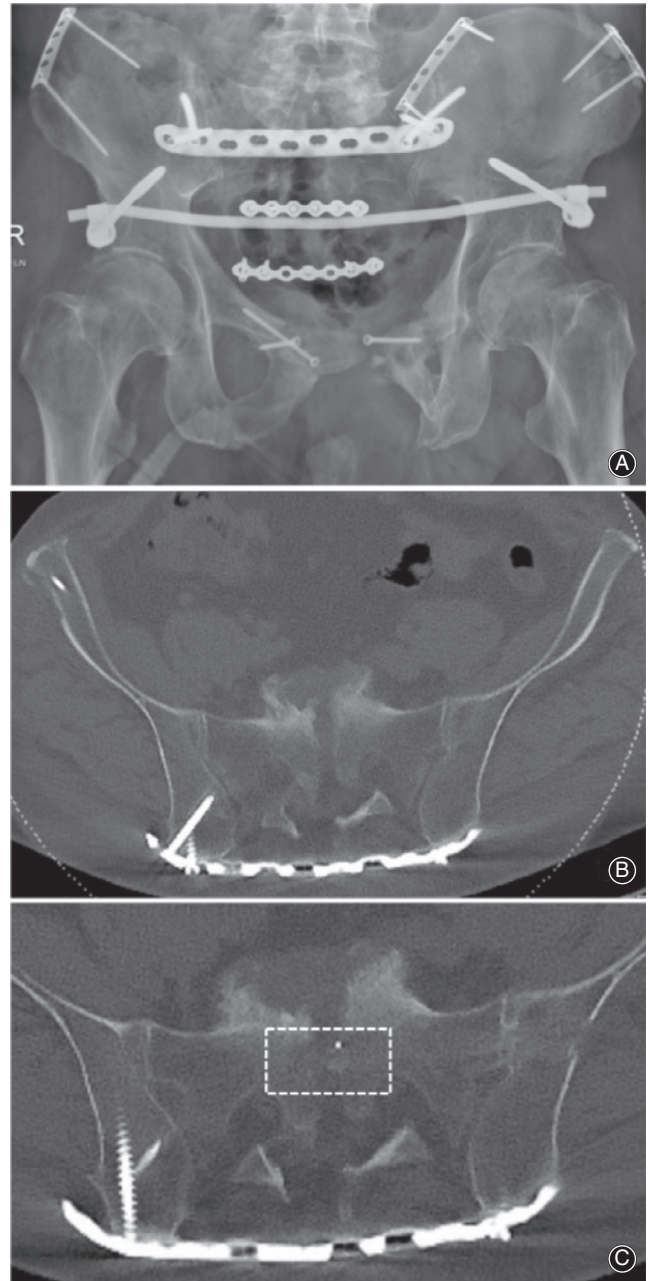


Fig. 8 Persistent nonunion of the sacrum (A, B) after C-type pelvic fracture and complicated course. The modified SDI-technique was applied to transplant an autologous bone cylinder to the area of nonunion (C, center of dashed rectangle).

scale 3) compared to his preoperative state (numeric analogue scale 6).

Case 3

The patient with the nonunion after periacetabular osteotomy (case 3) lives approximately 350 km away from our hospital and has not visited our outpatient department since

discharge. A phone interview revealed a great reduction of pain (now numeric analogue scale 3 vs 7 preoperatively). While she had been able to walk for only 500 m with crutches when she first presented to our department, she informed us that now she was able to walk without crutches and was planning to return to work, however with reduced daily working time. We were not able to access any postoperative CT-scans; her treating physician reports timely bone healing.

Case 4

The patient referred to as case 4 could be transferred to the urology department of our hospital shortly after the SDI-procedure. He underwent several operations to reconstruct the urinary bladder and restore urinary function. The latest CT-scan after the complicated course showed a slight increase of bone formation at the nonunion site 3 months after the SDI-procedure, however without complete bony bridging. Another 3 months later, the patient was able to walk without crutches and reported significant relief of pain.

Discussion

Malunions and nonunions after fractures of the pelvic ring are rare complications of rare injuries^{1–3,12–15}. An inadequate initial treatment seems to be the most common cause of pelvic nonunion or malunion^{13,26,27}. The treatment of pelvic nonunions is a challenging task even for experienced surgeons and is usually carried out in specialized centers.

The gold standard for the operative treatment of nonunions after pelvic fractures is a multi-stage approach with open debridement of the nonunion and internal fixation²⁶. Concerning the osteosynthesis, the attending surgeon has to choose from a wide range of implants, reaching from iliosacral screw fixation to plate fixation or lumbosacral and lumbosacral stabilization^{28–31}.

To provide a biological enhancement for bone healing, it is a standard procedure to transplant cancellous bone to the area of nonunion³². Usually, the autologous bone graft is harvested from the iliac crest and broken into small pieces of cancellous bone, which then are transferred to the area of

nonunion: a loose fitting transplant. Even if pushed firmly into the nonunion gap, only a limited fixation of the bone graft can be achieved with this technique. Furthermore, some of the small pieces are washed out again by intraoperative irrigation. The tight fitting of our SDI-harvested bone graft, however, prevents dislocation of the graft and provides ideal preconditions for bone healing due to its good bone-to-bone interface. This technique combines the mechanical advantage of a press-fit implant with the biological advantage of autologous bone transplants.

While the standard bone grafting procedure aims to induce bone formation in the whole area of nonunion at the pelvis, the transplantation of press-fit bone cylinders can only lead to partial healing. However, our technique led to a significant reduction of pain and a higher level of mobility in all cases. Therefore, we hypothesize that it might be more important to restore the integrity of the pelvic ring than to achieve a large area of bony bridging. This principle is commonly applied in the treatment of nonunions after transpubic fractures, where it is sufficient to stabilize one of the pubic rami.

Limitations

Obviously, the reported patient numbers are low, with inadequate follow up. The aim of this article was not to provide the scientific foundation for this treatment of a rare complication but, rather, to provide a first proof of concept for this mechanobiological approach to optimize nonunion healing conditions. Furthermore, prospective studies are now needed to determine the true value of this approach.

Conclusion

Through application of the modified SDI-technique, we herein demonstrated for the first time a standardized method for autologous transplantation of press-fit cancellous bone grafts in the treatment of pelvic nonunions. We found the technique to provide an excellent mechanobiological healing environment and did not observe any major disadvantages or complications. Providing further comparative studies, the modified SDI-technique could be a valid new treatment option for pelvic nonunions in the future.

References

- Balogh Z, King KL, Mackay P, et al. The epidemiology of pelvic ring fractures: a population-based study. *J Trauma*, 2007, 63: 1066–1073.
- Court-Brown CM, Caesar B. Epidemiology of adult fractures: a review. *Injury*, 2006, 37: 691–697.
- Pohlemann T, Tscherne H, Baumgartel F, et al. [Pelvic fractures: epidemiology, therapy and long-term outcome. Overview of the multicenter study of the Pelvis Study Group]. *Unfallchirurg*, 1996, 99: 160–167.
- Durkin A, Sagi HC, Durham R, Flint L. Contemporary management of pelvic fractures. *Am J Surg*, 2006, 192: 211–223.
- Giannoudis PV, Grotz MR, Tzioupis C, et al. Prevalence of pelvic fractures, associated injuries, and mortality: the United Kingdom perspective. *J Trauma*, 2007, 63: 875–883.
- Ragnarsson B, Jacobsson B. Epidemiology of pelvic fractures in a Swedish county. *Acta Orthop Scand*, 1992, 63: 297–300.
- O'Brien DP, Luchette FA, Pereira SJ, et al. Pelvic fracture in the elderly is associated with increased mortality. *Surgery*, 2002, 132: 710–714.
- Tosounidis G, Holstein JH, Culemann U, Holmenschlager F, Stuby F, Pohlemann T. Changes in epidemiology and treatment of pelvic ring fractures in Germany: an analysis on data of German Pelvic Multicenter Study Groups I and III (DGU/AO). *Acta Chir Orthop Traumatol Cech*, 2010, 77: 450–456.
- Culemann U, Scola A, Tosounidis G, Pohlemann T, Gebhard F. [Concept for treatment of pelvic ring injuries in elderly patients A challenge]. *Unfallchirurg*, 2010, 113: 258–271.
- Kannus P, Palvanen M, Niemi S, Parkkari J, Järvinen M. Epidemiology of osteoporotic pelvic fractures in elderly people in Finland: sharp increase in 1970–1997 and alarming projections for the new millennium. *Osteoporos Int*, 2000, 11: 443–448.
- Tosounidis G, Culemann U, Stengel D, et al. [Complex pelvic trauma in elderly patients]. *Unfallchirurg*, 2010, 113: 281–286.
- Tile M. *Fractures of the Pelvis and Acetabulum*, 3rd edn. Baltimore: Williams & Wilkins, 2003.

- 13.** Matta JM, Dickson KF, Markovich GD. Surgical treatment of pelvic nonunions and malunions. *Clin Orthop Relat Res*, 1996, 329: 199–206.
- 14.** Pennal GF, Massiah KA. Nonunion and delayed union of fractures of the pelvis. *Clin Orthop Relat Res*, 1980, 151: 124–129.
- 15.** Vanderschot P, Daenens K, Broos P. Surgical treatment of post-traumatic pelvic deformities. *Injury*, 1998, 29: 19–22.
- 16.** Lee KJ, Min BW, Oh GM, Lee SW. Surgical correction of pelvic Malunion and nonunion. *Clin Orthop Surg*, 2015, 7: 396–401.
- 17.** Tripathy SK, Goyal T, Sen RK. Nonunions and malunions of the pelvis. *Eur J Trauma Emerg Surg*, 2015, 41: 335–342.
- 18.** Brittberg M, Lindahl A, Nilsson A, Ohlsson C, Isaksson O, Peterson L. Treatment of deep cartilage defects in the knee with autologous chondrocyte transplantation. *N Engl J Med*, 1994, 331: 889–895.
- 19.** Laprell H, Petersen W. Autologous osteochondral transplantation using the diamond bone-cutting system (DBCS): 6-12 years' follow-up of 35 patients with osteochondral defects at the knee joint. *Arch Orthop Trauma Surg*, 2001, 121: 248–253.
- 20.** Wagner H. Surgical treatment of osteochondritis dissecans, a cause of arthritis deformans of the knee. *Rev Chir Orthop Reparatrice Appar Mot*, 1964, 50: 335–352, [].
- 21.** Draenert K. *Autologous Resurfacing and Fracture Dowelling: A Manual of Transplantation Technique*. Heidelberg, New York: Springer, 2012.
- 22.** Draenert K, Draenert Y. Autologous resurfacing. *Microsc Res Tech*, 2015, 78: 40–51.
- 23.** Bobic V. [Autologous osteo-chondral grafts in the management of articular cartilage lesions]. *Orthopade*, 1999, 28: 19–25.
- 24.** Horas U, Pelinkovic D, Herr G, Aigner T, Schnettler R. Autologous chondrocyte implantation and osteochondral cylinder transplantation in cartilage repair of the knee joint. A prospective, comparative trial. *J Bone Joint Surg Am*, 2003, 85-A: 185–192.
- 25.** Schnettler R, Horas U, Meyer C. [Autologous osteochondral transplants]. *Orthopade*, 2008, 37: 734–742.
- 26.** Nicodemo A, Capella M, Deregis M, Massè A. Nonunion of a sacral fracture refractory to bone grafting: internal fixation and osteogenic protein-1 (BMP-7) application. *Musculoskelet Surg*, 2011, 95: 157–161.
- 27.** Oransky M, Tortora M. Nonunions and malunions after pelvic fractures: why they occur and what can be done? *Injury*, 2007, 38: 489–496.
- 28.** Matta JM, Saucedo T. Internal fixation of pelvic ring fractures. *Clin Orthop Relat Res*, 1989, 242: 83–97.
- 29.** Matta JM, Tornetta P 3rd. Internal fixation of unstable pelvic ring injuries. *Clin Orthop Relat Res* 1996, 329: 129-140.
- 30.** Tornetta P 3rd, Matta JM. Outcome of operatively treated unstable posterior pelvic ring disruptions. *Clin Orthop Relat Res*, 1996, 329: 186–193.
- 31.** Tscherne H, Pohlemann T. *Becken und Acetabulum: Mit 30 Tabellen*. Berlin: Springer, 1998.
- 32.** Kanakaris NK, Angoules AG, Nikolaou VS, Kontakis G, Giannoudis PV. Treatment and outcomes of pelvic malunions and nonunions: a systematic review. *Clin Orthop Relat Res*, 2009, 467: 2112–2124.