

Interesting Images

Mind the Pitfall: Solitary Nodular Fasciitis Mimicking Extra-Nodal Manifestation of Hodgkin Lymphoma on [¹⁸F]FDG PET/CT

Suginthan Markandu ^{1,*}, Arne Blicke ¹, Caroline Burgard ¹ , Marc Remke ², Katrin Altmeyer ³, Mathias Wagner ⁴, Samer Ezziddin ¹  and Florian Rosar ¹ 

¹ Department of Nuclear Medicine, Saarland University, 66421 Homburg, Germany; arne.blicke@uni-saarland.de (A.B.); caroline.burgard@uks.eu (C.B.); samer.ezziddin@uks.eu (S.E.); florian.rosar@uks.eu (F.R.)

² Department of Pediatric Oncology and Hematology, Saarland University, 66421 Homburg, Germany; marc.remke@uks.eu

³ Department of Radiology, Saarland University, 66421 Homburg, Germany; katrin.altmeyer@uks.eu

⁴ Department of Pathology, Saarland University, 66421 Homburg, Germany; mathias.wagner@uks.eu

* Correspondence: suginthan.markandu@usk.eu; Tel.: +49-6841-162220

Abstract: We report a [¹⁸F]fluorodeoxyglucose positron emission tomography/computed tomography ([¹⁸F]FDG PET/CT) scan of a 17-year-old male presenting increased focal glucose metabolism of a histologically proven solitary nodular fasciitis mimicking an extranodal manifestation of Hodgkin lymphoma. This interesting image should draw attention to considering nodular fasciitis as a possible pitfall in the staging of malignant diseases.

Keywords: nodular fasciitis; Hodgkin lymphoma; FDG PET/CT; pitfall



Citation: Markandu, S.; Blicke, A.; Burgard, C.; Remke, M.; Altmeyer, K.; Wagner, M.; Ezziddin, S.; Rosar, F. Mind the Pitfall: Solitary Nodular Fasciitis Mimicking Extra-Nodal Manifestation of Hodgkin Lymphoma on [¹⁸F]FDG PET/CT. *Diagnostics* **2024**, *14*, 783. <https://doi.org/10.3390/diagnostics14080783>

Academic Editor: Andor W.J.M. Glaudemans

Received: 23 February 2024

Revised: 3 April 2024

Accepted: 4 April 2024

Published: 9 April 2024



Copyright: © 2024 by the authors. Licensee MDPI, Basel, Switzerland. This article is an open access article distributed under the terms and conditions of the Creative Commons Attribution (CC BY) license (<https://creativecommons.org/licenses/by/4.0/>).

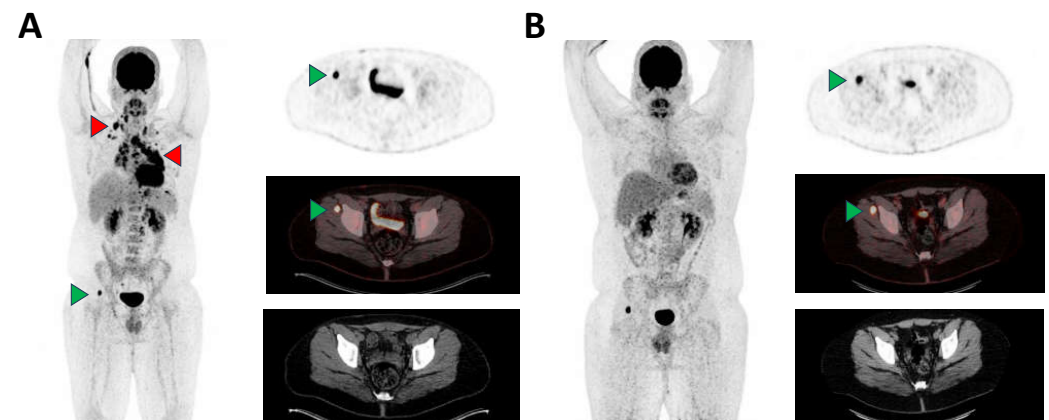


Figure 1. A 17-year-old male with histologically confirmed EBV-negative nodular sclerosing Hodgkin lymphoma (NSHL) was presented to our nuclear medicine department for staging. The [¹⁸F]FDG PET/CT showed extensive cervical, thoracic (mediastinal, hilar, pericardial, axillary and retrocrural) and abdominal (retroperitoneal, left iliac) nodal and extranodal pleural manifestations (A), exemplary red arrowheads, maximum standardized uptake value (SUVmax) up to 25.2). Additionally, the baseline staging revealed an intense focal (peri)muscular glucose metabolism in the lateral part of the right musculus gluteus minimus without any correlation on low-dose CT (A), green arrowhead, SUVmax 26.1). This finding was initially thought to be an additional extranodal manifestation of lymphoma. While all other nodal and extranodal manifestations of NSHL demonstrated complete metabolic remission after induction therapy, the finding remained with unchanged elevated glucose

metabolism (B), green arrowhead, SUVmax 19.1). For further clarification, magnetic resonance imaging (MRI) was performed showing a circular, marginal contrast-enhancing lesion of approx. 2 cm diameter with central sparing and positive fascial tail sign (Figure 2A). A subsequent MRI-guided biopsy revealed an EBV-negative spindle cell lesion reactive with monoclonal antibodies to alpha-actin (1:700; clone 1A4; DAKO Agilent Technologies, Santa Clara, CA, United States) and classified as a solitary nodular fasciitis (Figure 2B,C), a benign soft tissue tumor, which is characterized by a fast-growing nature and high mitotic count [1,2]. While prevalence of nodular fasciitis in the pediatric population is relatively low, with only 10% of all reported cases being children, tumor location in the muscles of the lower extremities is rarely reported, with the most common tumor sites being described in the upper extremities or in the head and neck [3–5]. The observed [^{18}F]FDG avidity of the nodular fasciitis lesion is presumably based on the increased glucose utilization due to the high proliferation rate. Clear differentiation of nodular fasciitis from viable extranodal manifestation of malignant lymphoma appears to be challenging on [^{18}F]FDG PET/CT imaging [6–9]. In addition, there is a variety of other known benign diseases which could also mimic malign manifestations on [^{18}F]FDG PET/CT [10–14].

Furthermore, it is known that lesions of nodular fasciitis tend to also show increased uptake of PSMA-targeted tracers, which may cause potential pitfalls for other tracers as well [15,16]. Magnetic resonance imaging seems to be a feasible complementary modality for further non-invasive differentiation [17,18]. This interesting image should draw attention to considering nodular fasciitis as a possible pitfall in the staging of malignant diseases on [^{18}F]FDG PET/CT.

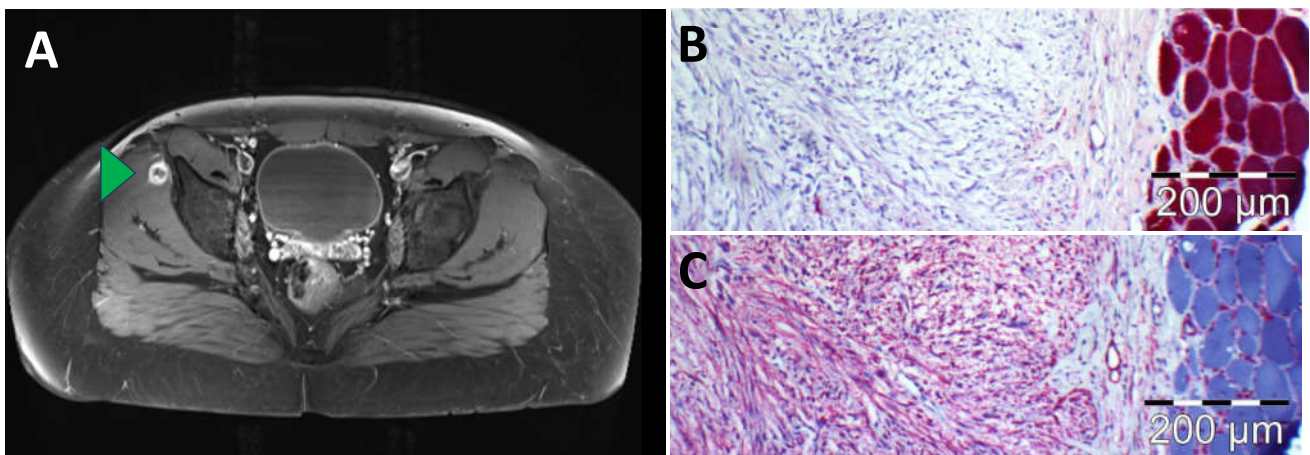


Figure 2. (A) Magnetic resonance imaging (MRI) with contrast-enhanced T1 TSE (Turbo Spin Echo) sequence and fat saturation showing a circular, marginal contrast-enhancing lesion with central sparing and positive fascial tail sign (green arrowhead); (B) immunohistochemistry revealed that lesional spindle cells hardly interact with anti-alpha gamma actin; (C) immunohistochemistry disclosed that lesional spindle cells strongly react with antibodies to alpha actin.

Author Contributions: Conceptualization, S.M., C.B., F.R., M.W. and S.E.; investigation, S.M., C.B., S.E. and F.R.; writing—original draft preparation, S.M., A.B., C.B. and F.R.; writing—review and editing, M.R., K.A. and M.W.; visualization, A.B. and M.W.; supervision, S.E. All authors have read and agreed to the published version of the manuscript.

Funding: This research received no external funding.

Institutional Review Board Statement: Ethical review and approval were waived for this report due to its retrospective case description, which did not impact the management of the patient.

Informed Consent Statement: Written informed consent has been obtained from the patient to publish this paper.

Data Availability Statement: The datasets used and analyzed in this paper are available from the corresponding author on reasonable request.

Acknowledgments: We are grateful to M. Ertz and E. Stenzhorn, Department of Pathology, Saarland University, for their technical assistance.

Conflicts of Interest: The authors declare no conflicts of interest.

References

1. Samaratunga, H.; Searle, J.; O'Loughlin, B. Nodular Fasciitis and Related Pseudosarcomatous Lesions of Soft Tissues. *Aust. N. Z. J. Surg.* **1996**, *66*, 22–25. [[CrossRef](#)] [[PubMed](#)]
2. Berry, A.B.; Jaffee, I.; Greenberg, M.; Eisele, D.W.; Ljung, B.-M. Nodular Fasciitis: Definitive Diagnosis by Fine Needle Aspiration. *Acta Cytol.* **2016**, *60*, 19–24. [[CrossRef](#)] [[PubMed](#)]
3. Hseu, A.; Watters, K.; Perez-Atayde, A.; Silvera, V.M.; Rahbar, R. Pediatric Nodular Fasciitis in the Head and Neck: Evaluation and Management. *JAMA Otolaryngol. Head. Neck Surg.* **2015**, *141*, 54–59. [[CrossRef](#)] [[PubMed](#)]
4. Tomita, S.; Thompson, K.; Carver, T.; Vazquez, W.D. Nodular Fasciitis: A Sarcomatous Impersonator. *J. Pediatr. Surg.* **2009**, *44*, e17–e19. [[CrossRef](#)] [[PubMed](#)]
5. Pandian, T.K.; Zeidan, M.M.; Ibrahim, K.A.; Moir, C.R.; Ishitani, M.B.; Zarroug, A.E. Nodular Fasciitis in the Pediatric Population: A Single Center Experience. *J. Pediatr. Surg.* **2013**, *48*, 1486–1489. [[CrossRef](#)] [[PubMed](#)]
6. Kim, J.Y.; Park, J.; Choi, Y.Y.; Lee, S.; Paik, S.S. Nodular Fasciitis Mimicking Soft Tissue Metastasis on ¹⁸F-FDG PET/CT during Surveillance. *Clin. Nucl. Med.* **2015**, *40*, 172–174. [[CrossRef](#)] [[PubMed](#)]
7. Barat, M.; Soyer, P.; Audard, V. Nodular Fasciitis: PET/CT and MR Imaging Features. *Diagn. Interv. Imaging* **2023**, *104*, 451–452. [[CrossRef](#)] [[PubMed](#)]
8. Kessels, L.W.; Simsek, S.; van Hattum, A.H.; Stam, F.; Comans, E.F.I. Nodular Fasciitis: An Unexpected Finding on Computed Tomography and Positron Emission Tomography. *Eur. J. Intern. Med.* **2004**, *15*, 183–185. [[CrossRef](#)] [[PubMed](#)]
9. Gotthardt, M.; Arens, A.; van der Heijden, E.; de Geus-Oei, L.-F.; Oyen, W.J.G. Nodular Fasciitis on F-18 FDG PET. *Clin. Nucl. Med.* **2010**, *35*, 830. [[CrossRef](#)] [[PubMed](#)]
10. Zhou, Q.; Ansari, U.; Keshav, N.; Davis, F.; Cundiff, M. Extranodal manifestation of Rosai-Dorfman disease in the breast tissue. *Radiol. Case Rep.* **2016**, *11*, 125–128. [[CrossRef](#)] [[PubMed](#)]
11. Dubreuil, J.; Salles, G.; Bozzetto, J.; Tordo, J.; Djaïleb, L.; Berriolo-Riedinger, A.; Leenhardt, J.; Giammarile, F.; Meignan, M.; Skanjeti, A. Usual and unusual pitfalls of 18F-FDG-PET/CT in lymphoma after treatment: A pictorial review. *Nucl. Med. Commun.* **2017**, *38*, 563–576. [[CrossRef](#)] [[PubMed](#)]
12. Schwerz, S.; Mueller, M.; Lindemann-Docter, K.; Heinzl, A.; Mottaghy, F.M.; Beheshti, M. Hepatic candidiasis mimicking lymphoma on ¹⁸F-FDG PET/CT in a patient with T cell lymphoma. *Eur. J. Nucl. Med. Mol. Imaging* **2020**, *47*, 2925–2926. [[CrossRef](#)] [[PubMed](#)]
13. Akkawi, A.R.; Ezzeddine, L.; Chahinian, R.; Ershaid, F.; Merheb, D.; Mzeihem, M.; El-Cheikh, J.; Haidar, M. Hepatic granuloma mimicking recurrent lymphoma on ¹⁸F-FDG PET/CT in a patient with primary mediastinal diffuse large B-cell lymphoma. *Asia Ocean. J. Nucl. Med. Biol.* **2022**, *10*, 47–52. [[CrossRef](#)] [[PubMed](#)]
14. Bryant, B.S.; Marsh, K.A.; Beuerlein, W.J.; Kalil, D.; Shah, K.K. A Case of Sarcoidosis Mimicking Lymphoma Confounded by Cognitive Decline. *Cureus* **2021**, *13*, e13667. [[CrossRef](#)] [[PubMed](#)]
15. Henninger, M.; Maurer, T.; Hacker, C.; Eiber, M. ⁶⁸Ga-PSMA PET/MR Showing Intense PSMA Uptake in Nodular Fasciitis Mimicking Prostate Cancer Metastasis. *Clin. Nucl. Med.* **2016**, *41*, e443. [[CrossRef](#)] [[PubMed](#)]
16. Plouznikoff, N.; Artigas, C.; Karfis, I.; Flamen, P. Low ⁶⁸Ga-PSMA PET/CT Uptake in Chronic Intramuscular Nodular Fasciitis. *Clin. Nucl. Med.* **2020**, *45*, e41. [[CrossRef](#)] [[PubMed](#)]
17. Nagano, H.; Kiyosawa, T.; Aoki, S.; Azuma, R. A Case of Nodular Fasciitis That Was Difficult to Distinguish from Sarcoma. *Int. J. Surg. Case Rep.* **2019**, *65*, 27–31. [[CrossRef](#)] [[PubMed](#)]
18. Della Volpe, A.; Festa, P.; Varricchio, A.M.; Russo, C.; Covelli, E.M.; Bifano, D.; Piroli, P.; De Lucia, A.; Di Stadio, A.; Ionna, F. Diagnosis and Treatment of Nodular Fasciitis of Ear Region in Children: A Case Report and Review of Literature. *Healthcare* **2022**, *10*, 1962. [[CrossRef](#)] [[PubMed](#)]

Disclaimer/Publisher's Note: The statements, opinions and data contained in all publications are solely those of the individual author(s) and contributor(s) and not of MDPI and/or the editor(s). MDPI and/or the editor(s) disclaim responsibility for any injury to people or property resulting from any ideas, methods, instructions or products referred to in the content.