


CASE REPORT

Immune-mediated thrombotic thrombocytopenic purpura in a Jehovah's Witness – Effectiveness of incorporating extracorporeal immunoadsorption to caplacizumab, steroids and rituximab

Teresa Marta Cardesa-Salzmann¹  | Bernhard Stephan² | Arne Simon¹ |
 Rhoikos Furtwängler¹ | Dominik Schöndorf¹ | Sabine Heine¹ | Eyad Torfah¹ |
 Margaux Lux¹ | Sonja Meyer¹ | Norbert Graf¹

¹Department of Pediatric Hematology & Oncology, Universitätsklinikum des Saarlandes, Homburg, Germany

²Department of Hemostaseology and Transfusion Medicine, Universitätsklinikum des Saarlandes, Homburg, Germany

Correspondence

Teresa Marta Cardesa-Salzmann,
 Kirrberger Straße Gebäude 9, 66421
 Homburg/Saar, Germany.
 Email: teresa.cardesa@uks.eu

Funding information

This case report received no funding

Abstract

We report the case of a Jehovah's Witness adolescent patient with immune-mediated thrombotic thrombocytopenic purpura after SARS-Cov2 infection successfully treated without therapeutic plasma exchange (TPE) using caplacizumab, corticosteroids, rituximab, and extracorporeal immunoadsorption (EIA). Further patients for whom TPE is not an option might benefit from this approach.

KEYWORDS

caplacizumab, immune-mediated TTP – SARS-Cov2, immunoadsorption, Jehovah's Witness, therapy without therapeutic plasma exchange

1 | INTRODUCTION

Without rapid recognition and treatment, thrombotic thrombocytopenic purpura (TTP) is potentially lethal. The pathophysiology of this thrombotic microangiopathy relies on a severe functional deficiency of ADAMTS-13 (activity <10%), which functions as the von Willebrand factor (VWF) cleavage protease, resulting in an accumulation of high molecular weight multimers of VWF with subsequent formation of platelet-rich microthrombi in the microvessels, organ ischemia and appearance of microangiopathic hemolytic anemia and consumptive thrombocytopenia.¹ In immune-mediated TTP (i-TTP), the mechanism for ADAMTS-13 severe deficiency is acquired

via IgG autoantibodies to ADAMTS-13.² The initial historic mortality rate >90% was revolutionized by prompt therapy with TPE with fresh frozen plasma replacement,³ which supplies adequate ADAMTS-13 levels while removing circulating autoantibodies against ADAMTS-13. Front-line therapy for i-TTP includes TPE, immunosuppression with corticosteroids, rituximab and if available, therapy with caplacizumab.⁴ For a Jehovah's Witness (JW) patient, therapy of this life-threatening condition implies a religious dilemma, since refusal of blood-component transfusions, in this case TPE therapy, is mandatory.

We report on the successful treatment without TPE of a JW adolescent patient with i-TTP after SARS-Cov2 infection who was treated with caplacizumab, corticosteroids,

This is an open access article under the terms of the [Creative Commons Attribution-NonCommercial-NoDerivs](https://creativecommons.org/licenses/by-nc-nd/4.0/) License, which permits use and distribution in any medium, provided the original work is properly cited, the use is non-commercial and no modifications or adaptations are made.

© 2022 The Authors. *Clinical Case Reports* published by John Wiley & Sons Ltd.

rituximab, and EIA. The published experiences regarding treatment of i-TTP in JW patients^{6–10} have not included EIA so far.

2 | CASE REPORT

A previously healthy 16-year-old male with a past medical history remarkable for a mildly symptomatic SARS-Cov-2 infection 3 months prior, was transferred to our hospital with sudden onset of aphasia, right sided hemianesthesia, and weakness of his right hand. On physical examination, he showed pallor and scattered ecchymosis and petechiae. The MRI of the brain was normal. His hemoglobin was 8.2 g/dl, hematocrit 22%, platelets 51,000/mm³, and leukocytes 7000/mm³, with reticulocytes of 12.12%. The blood smear showed abundant schistocytes; haptoglobin level was less than 5 mg/dl, LDH was 601 IU/ml (<372 IU/ml), and renal parameters were within normal limits. The direct and indirect Coombs tests were negative. ADAMTS-13 activity was below 0.3% (50%–110%), ADAMTS-13 antigen was 0.06 IU/ml (0.35–1.2 IU/ml) and the autoantibody against ADAMTS-13 was >99 IU/ml (<16 IU/ml), confirming the diagnosis of i-TTP. Antinuclear antibodies and antiphospholipid antibodies were negative. IgG against SARS-Cov-2 was positive (574 IU/ml), PCR for SARS-Cov-2 in the nasopharyngeal swab was negative; the patient had not undergone vaccination against COVID-19. A computed tomography of the chest was normal. Since urgent TPE therapy was firmly declined by the patient and his family, therapy with corticosteroids, caplacizumab, and rituximab was started (Figure 1). The patient received methylprednisolone 0.5 g/day intravenously (Days 1–3), caplacizumab 10 mg/

day (Days 2–45), first dose intravenously (IV), following doses subcutaneously, and rituximab 375 mg/m²/day IV (Days 1, 8, 15, and 22). Prednisolone was continued orally at 1 mg/kg/day (days 4–7), then at 0.5 mg/kg/day (days 8–14), subsequently at 0.3 mg/kg/day (days 15–27), with progressive reduction upon discontinuation on day 50. Rapidly after initiation of therapy with corticosteroids, caplacizumab, and rituximab, the patient attained normalization of the platelet count (Figure 1) with complete neurologic recovery.

Nevertheless, persistently low ADAMTS-13 activity and enduring high ADAMTS-13 autoantibodies were observed after four weeks of therapy (Figure 1). EIA was proposed as an alternative approach without TPE to remove circulating ADAMTS-13 antibodies from plasma. After written consent by the patient, his family and the institutional ethics committee, EIA was initiated. A Shaldon catheter was placed and EIA was started on day 29 (days 29–33) with Adsorber TR 350 and Plasma separator OP-05. Prior to and after each EIA session, fibrinogen levels were monitored; after the third EIA his fibrinogen level dropped to 61 mg/dl, requiring a single dose of fibrinogen concentrate substitution, which was accepted by the patient. After five EIA sessions at 24-hour intervals, the patient attained a rapid and sustained negativization of the ADAMTS-13 autoantibodies and normalization of ADAMTS-13 activity. No further immunosuppression was used after day 28, prednisolone was progressively reduced until withdrawal on day 50. Being off any further immunosuppressive therapy, he has remained in clinical remission, with a normal complete blood count, normal ADAMTS-13 activity, and negative ADAMTS-13 autoantibodies for more than 80 days after the cessation of therapy.

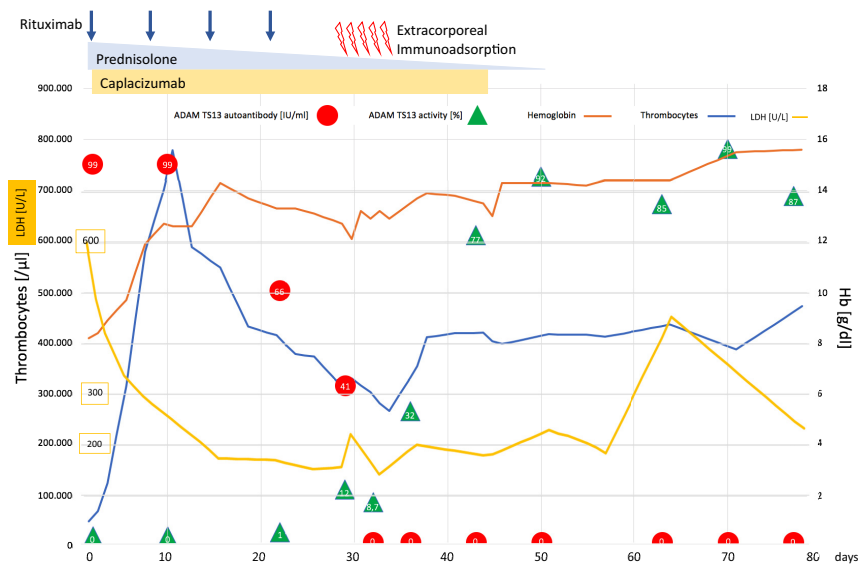


FIGURE 1 Thrombocyte count, hemoglobin level, LDH, ADAMTS-13 autoantibodies, and ADAMTS-13 activity in response to therapy with corticosteroids, caplacizumab, rituximab, and extracorporeal immunoabsorption therapy

3 | DISCUSSION

For a JW patient, therapy of this life-threatening condition implies a religious dilemma, since refusal of TPE is mandatory. The availability of targeted treatment strategies has broadened the scenario of therapeutic options in i-TTP.⁵ Caplacizumab, an anti-VWF nanobody that is a humanized, bivalent, variable-domain-only immunoglobulin fragment, inhibiting the interaction between VWF multimers and platelets, reduces platelet aggregation and secondary microvascular thrombosis, therefore mitigating ischemic organ damage. In the TITAN and HERCULES trials, early caplacizumab treatment showed faster resolution of the acute TTP episodes, quicker platelet count recovery, reduced i-TTP-related death, relapses, and major thromboembolic events.^{11,12} Caplacizumab rapidly improves the platelet count, end-organ damage and LDH, but it does not address the immunopathology of i-TTP. Persistently low ADAMTS-13 activity levels have been associated with an increased risk of relapse of i-TTP.¹³⁻¹⁵ Premature discontinuation of caplacizumab poses risk of disease exacerbation when the underlying autoimmune disease activity is not yet corrected. The optimal duration of caplacizumab is yet unclear. In this adolescent patient, although clinical remission was attained with caplacizumab, glucocorticoids, and rituximab, only a partial ADAMTS-13 remission was observed four weeks into treatment. EIA contributed through efficient removal of autoantibodies against ADAMTS-13, pivotal in the pathophysiology of i-TTP, to a rapid normalization of ADAMTS-13 activity, which allowed for discontinuation of caplacizumab in a setting of complete ADAMTS-13 remission (Figure 1). Remarkably, early, unexpected thrombocytosis was observed after 10 days of treatment with caplacizumab, steroids, and rituximab, which has been reported in patients with measurable inhibitors of ADAMTS-13 treated with caplacizumab.¹⁶ Glucocorticoids in conjunction with TPE remain a cornerstone in immunosuppressive therapy of acute i-TTP. Rituximab, a chimeric monoclonal antibody directed against CD20 which depletes CD20 (+) B-cells, targets suppression of the production of anti-ADAMTS-13 antibodies, contributing to restoration of function of the ADAMTS-13 protease. Rituximab immediately after TPE is currently used in the upfront setting of an initial episode of i-TTP since it has shown lower relapse rates compared with historical controls using TPE alone.¹⁷⁻¹⁹ While a rapid disappearance of anti-ADAMTS-13 antibodies was observed after EIA, durability of the maintained response in this case was likely due to the effect of rituximab and steroids.

It is hypothesized that refractory TTP will be less common in the era of caplacizumab,^{11,12} but in relapsed or

refractory cases cyclosporine A,²⁰ N-acetylcysteine,²¹ bortezomib,^{22,23} daratumomab,²⁴ cyclophosphamide, vincristine, or splenectomy²⁵ can be considered. Novel agents, such as recombinant ADAMTS13²⁶ also show promise for the treatment of TTP. The high cost of caplacizumab remains a major barrier to the addition of caplacizumab in all cases of i-TTP. A cost-effectiveness analysis of two clinical trials comparing the addition of caplacizumab to TPE plus immunosuppression showed that the addition of caplacizumab in all cases of i-TTP is not cost-effective and does not reduce the risk of relapse.²⁷

Nearly all JW patients refuse transfusions of whole blood and the primary blood components—red cells, platelets, and unfractionated plasma, but there is usually no objection to apheresis procedures and to the transfusion of derivatives of primary blood components such as albumin solutions, cryoprecipitate, immunoglobulins, and clotting factors. The initial historic mortality rate >90% was revolutionized by prompt therapy with TPE with fresh frozen plasma replacement.³ TPE remains a main element of standard of care upfront treatment approach of TTP since it supplies adequate ADAMTS-13 levels while removing circulating autoantibodies against ADAMTS-13. EIA is an apheresis procedure developed in the 1960s that relies on the separation of plasma of the patient, which is subsequently exposed to an immunoabsorption column that specifically removes IgG antibodies through high-affinity absorbers from the plasma before returning it to the patient, thus binding the ADAMTS-13 autoantibodies.²⁸ EIA negates the need for replacement of plasma and is therefore acceptable for JW patients. The use of EIA had been reported in the 1990s for refractory TTP²⁹ and for the treatment of cancer chemotherapy-associated thrombotic thrombocytopenic purpura/hemolytic uremic syndrome.³⁰ EIA is currently used for treatment of a large variety of antibody-mediated or immunological diseases (e.g., humoral transplant rejection, lupus nephritis, multiple sclerosis). After TPE or after EIA, hypofibrinogenemia needs to be monitored with the goal to maintain fibrinogen levels >100 mg/dl to minimize the risk of bleeding. EIA appears to be safer than TPE with regard to the risk of transient hypofibrinogenemia.³⁴ and EIA removes fibrinogen independently of the volume processed.³⁵ In this case, fibrinogen concentrate transfusion was required after the third session and was accepted by the patient.

The experience of successful treatment of i-TTP using caplacizumab, glucocorticoids, and rituximab without TPE, with clinical remission and restoration of ADAMTS-13 activity to normal had been reported in a JW patient.⁹ Further cases of i-TTP treated with caplacizumab, glucocorticoids, and rituximab without the use of TPE have been reported,^{31,32} also in the context of anaphylaxis to TTP.³³

While the majority of i-TTP cases are of unknown etiology, secondary i-TTP can be associated to certain autoimmune disorders like systemic lupus erythematosus, malignancies, medications, as well as viral infections like HIV,³⁶ CMV,³⁷ and SARS-CoV-2. SARS-CoV2 has been reported as a possible trigger for autoimmune and inflammatory dysregulation³⁸ including i-TTP, which has been described as a further dramatic life-threatening clinical presentation of SARS-Cov-2 infection.^{39–41} There have been several case reports describing the development of i-TTP secondary to COVID-19 infection in adults³⁹ and only one pediatric case.⁴² The majority of these cases had i-TTP concurrently with COVID-19 infection, but i-TTP has also been described after one month from SARS-Cov2 infection.^{41,42} The exact pathophysiology of COVID-associated a-TTP remains to be explained, but ADAMTS-13 inhibitors have been reported in other a-TTPs associated to RNA viral infections.⁴³ In the light of the magnitude of the pandemic, one might assume there may have been many more cases of COVID-associated i-TTP around the world, with possibly more cases to come.

Shared decision-making can facilitate changes of medical practice. Our experience in this case suggests that caplacizumab together with corticosteroids, rituximab, and EIA may be an effective treatment option for further patients with i-TTP who are unwilling to undergo TPE due to religious prohibitions, lack of availability or a history of severe immune reaction to plasma.

AUTHOR CONTRIBUTIONS

C-S.T wrote the article, C-S.T, S.B., S.A, and G.N. conceived this special report; all authors collected clinical data and contributed to manuscript preparation and approved its content.

ACKNOWLEDGEMENT

None.

CONFLICT OF INTEREST

The authors declare no conflicts of interest.

DATA AVAILABILITY STATEMENT

The authors confirm that the data supporting the findings of this case are available within the article. The data are anonymized.

ETHICAL APPROVAL

The treatment with extracorporeal immunoadsorption was approved by the institutional ethics committee.

CONSENT

The patient and his parents consented to receive treatment with extracorporeal immunoadsorption and with

fibrinogen concentrate. Written informed consent was obtained from the patient and his family to publish this report in accordance with the journal's patient consent policy.

ORCID

Teresa Marta Cardesa-Salzmänn  <https://orcid.org/0000-0003-2142-6898>

REFERENCES

1. Sukumar S, Lämmle B, Cataland SR. Thrombotic thrombocytopenic purpura: pathophysiology, diagnosis, and management. *J Clin Med*. 2021;10(3):536. doi:10.3390/jcm10030536
2. Mariotte E, Azoulay E, Galicier L, et al. Epidemiology and pathophysiology of adulthood-onset thrombotic microangiopathy with severe ADAMTS13 deficiency (thrombotic thrombocytopenic purpura): a cross-sectional analysis of the French national registry for thrombotic microangiopathy. *Lancet Haematol*. 2016;3(5):e237-e245. doi:10.1016/S2352-3026(16)30018-7
3. Rock GA, Shumak KH, Buskard NA, et al. Comparison of plasma exchange with plasma infusion in the treatment of thrombotic thrombocytopenic purpura. Canadian Apheresis Study Group. *N Engl J Med*. 1991;325(6):393-397. doi:10.1056/NEJM199108083250604
4. Joly BS, Coppo P, Veyradier A. Thrombotic thrombocytopenic purpura. *Blood*. 2017;129(21):2836-2846. doi:10.1182/blood-2016-10-709857
5. Mazepa MA, Masias C, Chaturvedi S. How targeted therapy disrupts the treatment paradigm for acquired TTP: the risks, benefits, and unknowns. *Blood*. 2019;134(5):415-420. doi:10.1182/blood.2019000954
6. George JN, Sandler SA, Stankiewicz J. Management of thrombotic thrombocytopenic purpura without plasma exchange: the Jehovah's Witness experience. *Blood Adv*. 2017;1(24):2161-2165. doi:10.1182/bloodadvances.2017012351
7. Baseri B, Vishwanathan S, Benasher D, Khazan M, Luhrs C, Tsai HM. Survival of a Jehovah's Witness with thrombotic thrombocytopenic purpura without using plasma: a case report and review of the literature. *J Clin Apher*. 2019;34(5):623-630. doi:10.1002/jca.21710
8. Chai W, Chaudhry A, Rabinowitz AP. Successful management of thrombotic thrombocytopenic purpura in a Jehovah's Witness without plasma exchange. *J Clin Apher*. 2015;30(1):46-49. doi:10.1002/jca.21325
9. Chander DP, Loch MM, Cataland SR, George JN. Caplacizumab therapy without plasma exchange for acquired thrombotic thrombocytopenic purpura. *N Engl J Med*. 2019;381(1):92-94. doi:10.1056/NEJMc1905426
10. Dabak V, Kuriakose P, Raman S. Successful management of a Jehovah's Witness with thrombotic thrombocytopenic purpura unwilling to be treated with therapeutic plasma exchange. *J Clin Apher*. 2007;22(6):330-332. doi:10.1002/jca.20150
11. Peyvandi F, Scully M, Kremer Hovinga JA, et al. Caplacizumab for acquired thrombotic thrombocytopenic purpura. *N Engl J Med*. 2016;374(6):511-522. doi:10.1056/NEJMoa1505533
12. Scully M, Cataland SR, Peyvandi F, et al. Caplacizumab treatment for acquired thrombotic thrombocytopenic purpura.

- N Engl J Med.* 2019;380(4):335-346. doi:10.1056/NEJMoA1806311
13. Page EE, Kremer Hovinga JA, Terrell DR, Vesely SK, George JN. Clinical importance of ADAMTS13 activity during remission in patients with acquired thrombotic thrombocytopenic purpura. *Blood.* 2016;128(17):2175-2178. doi:10.1182/blood-2016-06-724161
 14. Jin M, Casper TC, Cataland SR, et al. Relationship between ADAMTS13 activity in clinical remission and the risk of TTP relapse. *Br J Haematol.* 2008;141(5):651-658. doi:10.1111/j.1365-2141.2008.07107.x
 15. Peyvandi F, Lavoretano S, Palla R, et al. ADAMTS13 and anti-ADAMTS13 antibodies as markers for recurrence of acquired thrombotic thrombocytopenic purpura during remission. *Haematologica.* 2008;93(2):232-239. doi:10.3324/haematol.11739
 16. Gokozan HN, Reeves HM, Maitta RW. Absolute immature platelet count dynamics of thrombotic thrombocytopenic purpura patients with high ADAMTS13 inhibitor. *Thromb Res.* 2019;179:128-131. doi:10.1016/j.thromres.2019.05.011
 17. Page EE, Kremer Hovinga JA, Terrell DR, Vesely SK, George JN. Rituximab reduces risk for relapse in patients with thrombotic thrombocytopenic purpura. *Blood.* 2016;127(24):3092-3094. doi:10.1182/blood-2016-03-703827
 18. Scully M, McDonald V, Cavenagh J, et al. A phase 2 study of the safety and efficacy of rituximab with plasma exchange in acute acquired thrombotic thrombocytopenic purpura. *Blood.* 2011;118(7):1746-1753. doi:10.1182/blood-2011-03-341131
 19. Westwood JP, Webster H, McGuckin S, McDonald V, Machin SJ, Scully M. Rituximab for thrombotic thrombocytopenic purpura: benefit of early administration during acute episodes and use of prophylaxis to prevent relapse. *J Thromb Haemost.* 2013;11(3):481-490. doi:10.1111/jth.12114
 20. Cataland SR, Jin M, Lin S, Kraut EH, George JN, Wu HM. Effect of prophylactic cyclosporine therapy on ADAMTS13 biomarkers in patients with idiopathic thrombotic thrombocytopenic purpura. *Am J Hematol.* 2008;83(12):911-915. doi:10.1002/ajh.21281
 21. Li GW, Rambally S, Kamboj J, et al. Treatment of refractory thrombotic thrombocytopenic purpura with N-acetylcysteine: a case report. *Transfusion.* 2014;54(5):1221-1224. doi:10.1111/trf.12440
 22. Eskazan AE. Bortezomib therapy in patients with relapsed/refractory acquired thrombotic thrombocytopenic purpura. *Ann Hematol.* 2016;95(11):1751-1756. doi:10.1007/s00277-016-2804-x
 23. Shortt J, Oh DH, Opat SS. ADAMTS13 antibody depletion by bortezomib in thrombotic thrombocytopenic purpura. *N Engl J Med.* 2013;368(1):90-92. doi:10.1056/NEJMc1213206
 24. Pandey MR, Vachhani P, Ontiveros EP. Remission of severe, relapsed, and refractory TTP after multiple cycles of bortezomib. *Case Rep Hematol.* 2017;2017:9681832. doi:10.1155/2017/9681832
 25. Dubois L, Gray DK. Case series: splenectomy: does it still play a role in the management of thrombotic thrombocytopenic purpura? *Can J Surg.* 2010;53(5):349-355.
 26. Scully M, Knöbl P, Kentouche K, et al. Recombinant ADAMTS-13: first-in-human pharmacokinetics and safety in congenital thrombotic thrombocytopenic purpura. *Blood.* 2017;130(19):2055-2063. doi:10.1182/blood-2017-06-788026
 27. Goshua G, Sinha P, Hendrickson JE, Tormey C, Bendapudi PK, Lee AI. Cost effectiveness of caplacizumab in acquired thrombotic thrombocytopenic purpura. *Blood.* 2021;137(7):969-976. doi:10.1182/blood.2020006052
 28. Ohkubo A, Okado T, Miyamoto S, et al. Removal characteristics of immunoabsorption with the immusorba TR-350 column using conventional and selective plasma separators. *Ther Apher Dial.* 2016;20(4):360-367. doi:10.1111/1744-9987.12467
 29. Mittelman A, Puccio C, Ahmed T, et al. Response of refractory thrombotic thrombocytopenic purpura to extracorporeal immunoabsorption. *N Engl J Med.* 1992;326(10):711-712. doi:10.1056/NEJM199203053261015
 30. Snyder HW Jr, Mittelman A, Oral A, et al. Treatment of cancer chemotherapy-associated thrombotic thrombocytopenic purpura/hemolytic uremic syndrome by protein A immunoabsorption of plasma. *Cancer.* 1993;71(5):1882-1892. doi:10.1002/1097-0142(19930301)71:5<1882::aid-cnrc2820710527>3.0.co;2-e
 31. Sukumar S, George JN, Cataland SR. Shared decision making, thrombotic thrombocytopenic purpura, and caplacizumab. *Am J Hematol.* 2020;95(4):E76-E77. doi:10.1002/ajh.25715
 32. Völker LA, Brinkkoetter PT, Knöbl PN, et al. Treatment of acquired thrombotic thrombocytopenic purpura without plasma exchange in selected patients under caplacizumab. *J Thromb Haemost.* 2020;18(11):3061-3066. doi:10.1111/jth.15045
 33. Irani MS, Sanchez F, Friedman K. Caplacizumab for treatment of thrombotic thrombocytopenic purpura in a patient with anaphylaxis to fresh-frozen plasma. *Transfusion.* 2020;60(8):1666-1668. doi:10.1111/trf.15823
 34. Honoré PM, Jacobs R, De Waele E, Van Gorp V, Spapen HD. Immunoabsorption versus therapeutic plasma exchange. Will fibrinogen make the difference? *Blood Purif.* 2014;38(2):158-159. doi:10.1159/000369378
 35. Zöllner S, Pablik E, Druml W, Derfler K, Rees A, Biesenbach P. Fibrinogen reduction and bleeding complications in plasma exchange, immunoabsorption and a combination of the two. *Blood Purif.* 2014;38(2):160-166. doi:10.1159/000367682
 36. Brecher ME, Hay SN, Park YA. Is it HIV TTP or HIV-associated thrombotic microangiopathy? *J Clin Apher.* 2008;23(6):186-190. doi:10.1002/jca.20176
 37. Boteju M, Weeratunga P, Sivashangar A, Chang T. Cytomegalovirus induced refractory TTP in an immunocompetent individual: a case report. *BMC Infect Dis.* 2019;19(1):394. doi:10.1186/s12879-019-4037-9
 38. Dotan A, Muller S, Kanduc D, David P, Halpert G, Shoenfeld Y. The SARS-CoV-2 as an instrumental trigger of autoimmunity. *Autoimmun Rev.* 2021;20(4):102792. doi:10.1016/j.autrev.2021.102792
 39. Mir TH. Thrombotic microangiopathy (aHUS/iTTP) reported so far in Covid-19 patients: the virus alone or an omnium gatherum of mechanisms and etiologies? *Crit Rev Oncol Hematol.* 2021;162:103347. doi:10.1016/j.critrevonc.2021.103347
 40. Dhingra G, Maji M, Mandal S, Vaniyath S, Negi G, Nath UK. COVID 19 infection associated with thrombotic thrombocytopenic purpura. *J Thromb Thrombolysis.* 2021;52(2):504-507. doi:10.1007/s11239-021-02452-0
 41. Capecchi M, Mocellin C, Abbruzzese C, Mancini I, Prati D, Peyvandi F. Dramatic presentation of acquired thrombotic thrombocytopenic purpura associated with COVID-19.

- Haematologica*. 2020;105(10):e540. doi:[10.3324/haematol.2020.262345](https://doi.org/10.3324/haematol.2020.262345)
42. Hidalgo Filho CMT, Dalessandro Adamo DSM, Lopes CM, Martin EM. Thrombotic thrombocytopenic purpura associated with COVID-19 in a pediatric patient: case report. *Hematol Transfus Cell Ther*. 2021;43(3):349-352. doi:[10.1016/j.htct.2021.02.003](https://doi.org/10.1016/j.htct.2021.02.003)
43. Lopes da Silva R. Viral-associated thrombotic microangiopathies. *Hematol Oncol Stem Cell Ther*. 2011;4(2):51-59. doi:[10.5144/1658-3876.2011.51](https://doi.org/10.5144/1658-3876.2011.51)

How to cite this article: Cardesa-Salzmänn TM, Stephan B, Simon A, et al. Immune-mediated thrombotic thrombocytopenic purpura in a Jehovah's Witness – Effectiveness of incorporating extracorporeal immunoadsorption to caplacizumab, steroids and rituximab. *Clin Case Rep*. 2022;10:e05902. doi:[10.1002/ccr3.5902](https://doi.org/10.1002/ccr3.5902)