



Chronic renal failure as predictive factor for acute elevation of systolic blood pressure after fluorescein angiography in patients with retinal diseases

Alaa Din Abdin^{a,*}, Marie Hammerschmidt^a, Amine Maamri^a, Cristian Munteanu^a, Haring Bernhard^b, Böhm Michael^b, Berthold Seitz^a, Amr Abdin^b

^a Department of Ophthalmology, Saarland University Medical Center UKS, Homburg, Saar, Germany

^b Department of Internal Medicine III, Cardiology, Angiology and Internal Intensive Care Medicine, Saarland University Medical Center UKS, Homburg, Saar, Germany

ARTICLE INFO

Keywords:

Fluorescein angiography
Blood pressure
Side effects
Chronic renal failure

ABSTRACT

Purpose: To investigate the influence of fluorescein angiography (FA) on blood pressure (BP) in patients with retinal diseases, and analyze the predictive factors for acute elevation of systolic BP after FA.

Design: and **Methods:** A prospective study was conducted with 636 patients undergoing FA between April 2021 and October 2021. BP and pulse were measured in each patient before and 20 min after FA. The baseline characteristics of patients who developed an acute elevation in systolic BP (>10 mmHg) were compared with those of the remaining patients to detect factors that may predict this acute elevation.

Results: Overall, mean systolic BP changed from 142 ± 17 mmHg to 140 ± 20 mmHg after 20 min ($p = 0.1$). Mean diastolic BP changed from 79 ± 15 mmHg to 78 ± 13 mmHg after 20 min ($p = 0.45$). Mean pulse rate changed from 73 ± 14 bpm to 70 ± 12 bpm after 20 min ($p = 0.001$). 103 patients (16 %) had acute elevation of systolic BP (>10 mmHg). Mean systolic BP changed from 143 ± 17 mmHg to 162 ± 19 mmHg after 20 min in this group ($p = 0.001$). Patients in this group were significantly older compared to the rest (73 ± 12 vs 67 ± 15 , $p = 0.001$). The rate of chronic renal failure was significantly higher in this group compared to the rest of the patients (42/7.8 % vs 15/4.6 %, $p = 0.01$).

Conclusions: This study demonstrated that fluorescein angiography is a relatively safe procedure with regards to blood pressure changes. However, chronic renal failure could be considered as predictive factor for acute elevation of systolic blood pressure after this procedure.

1. Introduction

Fluorescein angiography (FA) has been a commonly used method for obtaining important diagnostic imaging for the retina since its invention [1].

Sodium fluorescein is an orange-red, crystalline, water-soluble hydrocarbon dye with a molecular weight of 332.3 g/mol. It

* Corresponding author. Alaa Din Abdin, FEBO, FICO, MRSCEd, Department of Ophthalmology, Saarland University Medical Center UKS, Kirrberger Strasse 100, Bldg. 22, 66421, Homburg, Saar, Germany.

E-mail address: alaadin.abdin@uks.eu (A.D. Abdin).

<https://doi.org/10.1016/j.heliyon.2023.e22700>

Received 14 February 2023; Received in revised form 29 August 2023; Accepted 16 November 2023

Available online 28 November 2023

2405-8440/© 2023 The Authors. Published by Elsevier Ltd. This is an open access article under the CC BY-NC-ND license (<http://creativecommons.org/licenses/by-nc-nd/4.0/>).

remains essentially intravascular when injected intravenously and circulates in the blood stream. Nevertheless, it crosses blood vessels and diffuses most rapidly into other body fluids when blood-tissue barriers are impaired. Fluorescein exhibits the physical property of fluorescing at 520–530 nm (green) when stimulated by light at 465–490 nm (blue) [2,3].

The FA provides insight into the arterial and venous vascular status and the manifestation of various internal and ophthalmological disorders. It is frequently used as a routine and follow-up examination in known diabetes mellitus for early detection of diabetic retinopathy; in age-related macular degeneration (AMD); in retinal perfusion disorders such as retinal arterial and venous occlusion; in anterior ischemic optic neuropathy and other ocular or vascular diseases [4–7].

Following the introduction of optical coherence tomography angiography (OCTA), which is non-invasive compared to FA, FA has recently become less used, especially for monitoring clinical progression. OCTA is a novel imaging technique that identifies vascular structures based on motion or flow characteristics. It offers fast, non-invasive, depth-resolved vascular imaging information. However, there are still a few conditions that require the use of FA, which provides a wide-angle examination of the retina and detects vascular leakage [8].

Although fluorescein is a relatively safe agent, significant side effects have been reported in the literature, some of them are common, such as yellowing of the skin and urine, as well as mild side effects including nausea, vomiting, redness of the skin, itching, and sneezing. Serious but rare side effects have also been reported such as severe vasovagal reactions, syncope, laryngeal edema, bronchospasm, and anaphylactic shock in less than 1 in 100,000 injections [2,3].

Fluorescein is reported to cross the placenta and could carry a potential risk to the fetus. The US Food and Drug Administration (FDA) has classified fluorescein as pregnancy category C [9]. The Fluorescein Sodium product information indicates that insufficient studies have been conducted to evaluate safety in pregnant women and that use should be limited to cases where it is strongly indicated, with caution that it should be avoided, especially in the first trimester [10]. On the other hand, some clinical reports concluded that FA does not correlate with a high rate of birth anomalies or complications during pregnancy [11].

However, in the literature, there is little evidence for cardiovascular side effects of FA. Nevertheless, some concerns have been raised about a potential role of arterial hypertension before and after FA, especially in elderly patients, and therefore hypertension is considered a relative contraindication to FA in previous reports [12]. At the Saarland University Medical Center (UKS), we observed an acute increase in arterial blood pressure (BP) in some of our patients. Consequently, the present prospective study aimed to investigate the influence of FA on BP and pulse in patients with retinal diseases. In addition, we analyzed the predictive factors for acute elevation of systolic BP after FA.

2. Methods

This prospective study was conducted including 636 adult patients (>18 years) undergoing indicated FA in the Department of Ophthalmology at Saarland University Medical Center between April 2021 and October 2021. Informed consent was taken from each patient before the procedure. Baseline clinical and demographic parameters were obtained from the electronic medical records.

Our exclusion criteria were pregnancy, elevated BP before FA (systolic >180 mmHg, diastolic >100 mmHg), bilateral mastectomy and known allergy to fluorescein. Patients taking beta-blocker tablets or using beta-blocker-containing eye drops were closely monitored as they may be at increased risk of attenuated vascular compensatory responses to anaphylactic shock.

2.1. Fluorescein angiography (FA)

FA (HRA2; Heidelberg Engineering, Heidelberg, Germany) was performed according to the normal existing standard. After an image of the retina was taken under normal illumination, mydriasis was induced by Tropicamide 5 mg/1 ml and Phenylephrine 2.5 % eye drops. Subsequently, after careful selection of an appropriate arm, an intravenous line was opened, through which fluorescein (2.5 ml of a 10 % solution, Alcon Pharma GmbH, Freiburg, Germany) was administered. Arm retinal time was then immediately measured, followed by acquisition of the ocular fundus assessment images in the prearterial, arterial, arteriovenous, and venous phases at fixed time intervals. The examination lasted a maximum of 20 min and was completely painless. Subsequently, approximately 20 min after the FA, patients were questioned again regarding various symptoms, such as skin lesions, stomach pain, nausea, vomiting, shortness of breath, chest pain, dizziness and palpitations.

2.2. Blood pressure (PB) measurement

BP and pulse were measured before and 20 min after FA. To minimize the effects of stress, the patient sat comfortably in a chair with a backrest and placed his/her feet on the floor before the measurement. Ideally, the patient should be relaxed, not speak and remain in this position for at least 5 min. It was also noted that there were no contraindications to the use of the chosen arm, such as lymphedema, recent trauma or surgery, or arteriovenous fistula. If any problems existed, the other arm was used. An appropriately sized cuff was chosen, with the inflatable bladder enclosing at least 80 % of the arm. The cuff was placed on the bare upper arm about one inch above the bend of the elbow. If the BP had to be repeated due to illegible or unreliable values, there was a waiting time of at least 1 min before each measurement [13]. For this study, Philips Efficia CM100 electronic monitors were used to measure BP (accuracy - Maximum SD \leq 8 mmHg - Maximum ME: \pm 5 mmHg). The pulse rate was continuously measured with the same monitor system. Adequate time was allowed to detect any irregularities in strength or rhythm.

2.3. Definition of arterial hypertension

The clinical and demographic parameters were taken from the electronic medical records. If the diagnosis of hypertension was known from the medical history and the patients were taking antihypertensive medication, the diagnosis of hypertension was made. If hypertension was not known, arterial hypertension was defined as “systolic blood pressure ≥ 140 mmHg and/or diastolic blood pressure ≥ 90 mmHg” measured at least two different time points [14]. In this case, we sent the patient to the cardiology department for further evaluation.

Main outcome measures included:

- Systolic BP
- Diastolic BP
- Pulse
- Other side effects

In addition, baseline characteristics were compared between patients with acute elevation of systolic BP (>10 mmHg) and the remaining patients to detect any factors predictive of this acute elevation.

Ethical approval: This study was approved by the Ethics Committee of the Medical Association of Saarland, Germany (No. 129/21).

Statistical analysis: IBM SPSS version 27 was used for statistical analysis. To test for normality of distribution we used the Kolmogorov-Smirnov test. We further looked at all the significant parameters describing the distribution (such as Mean, SD, Median, Skewness and Kurtosis) as well as the histogram and Q-Q plots. The final decision regarding the distribution was based on all the mentioned elements using the approach of Peat et al. [15]. Continuous data are presented as mean \pm standard deviation, skewed continuous parameters were expressed as median (interquartile range defined as Q1–Q3). Categorical data were summarized as frequencies and percentages and were compared using χ^2 test. Comparisons between baseline characteristics were performed with the independent Student's t-test for the continuous variable (age), as it was normally distributed, and with the χ^2 -test for the categorical variables (sex and comorbidities). To analyze the association between baseline and the rise in BP, binary logistic regression analysis was used. Parameters that were found to be univariate associated with the outcome and those that show a slight association with the outcome with $p < 0.20$ were included in the multivariable analysis. A P value of <0.05 was considered statistically significant.

3. Results

3.1. Baseline characteristics

The mean age of all patients was 67.5 ± 15 years. 427 (67.1 %) of all patients reported arterial hypertension, while 229 (36 %) reported diabetes mellitus and 57 (9 %) reported chronic renal failure. A summary of baseline characteristics for all patients is shown in Table 1.

3.2. Changes of blood pressure (BP) for all patients

The mean systolic BP changed from 142.2 ± 17 to 140.9 ± 20 ($p = 0.1$) after 20 min (Fig. 1). The mean diastolic BP changed from 79.0 ± 15 to 78.2 ± 13 ($p = 0.45$) after 20 min (Fig. 1). The mean pulse rate changed after 20 min from 72.7 ± 14 to 70.0 ± 12 ($p = 0.001$). We did not observe any significant difference in BP between patients receiving beta-blockers-containing eye drops and other patients.

Patients with acute systolic BP elevation:

Table 1

Baseline characteristics and BP changes for all patient and patients with acute elevation of systolic BP after FA (>10 mmHg) compared to other patients (≤ 10 mmHg).

Variable	all patients (n = 636)	systolic BP (≤ 10 mmHg) (n = 533)	systolic BP (>10 mmHg) (n = 103)	p-value
Age (years)	67.5 ± 15	67.5 ± 15	73.8 ± 12	0.001
Male:Female %	54 %:46 %	54 %:46 %	53 %:47 %	0.53
Heart failure	30 (4.7 %)	23 (4.3 %)	7 (6.8 %)	0.36
Diabetes mellitus	229 (36 %)	189 (35.4 %)	40 (38.8 %)	0.79
Cerebrovascular accident	53 (8.3 %)	46 (8.6 %)	7 (6.7 %)	0.32
Smoking	84 (13.2 %)	76 (14.2 %)	8 (7.8 %)	0.20
Coronary heart disease	115 (18.1 %)	92 (15.3 %)	23 (22.3 %)	0.21
Atrial fibrillation	89 (14.1 %)	69 (12.9 %)	20 (19.4 %)	0.05
Arterial hypertension	427 (67.1 %)	349 (65.4 %)	78 (76.5 %)	0.08
Chronic renal failure	57 (9 %)	42 (7.8 %)	15 (14.6 %)	0.01
Systolic BP	$142.2 \pm 17 \rightarrow 140.9 \pm 20$	$142.0 \pm 16 \rightarrow 136.6 \pm 14$	$142.8 \pm 17 \rightarrow 161.8 \pm 19$	-
Diastolic BP	$79.0 \pm 15 \rightarrow 78.2 \pm 13$	$79.2 \pm 9 \rightarrow 78.8 \pm 9$	$79.8 \pm 17 \rightarrow 82.5 \pm 20$	-
Pulse rate	$72.7 \pm 14 \rightarrow 70.0 \pm 12$	$72.5 \pm 10 \rightarrow 69.8 \pm 10$	$70.5 \pm 12 \rightarrow 73.0 \pm 16$	-

BP: Blood pressure, FA: Fluorescein angiography.

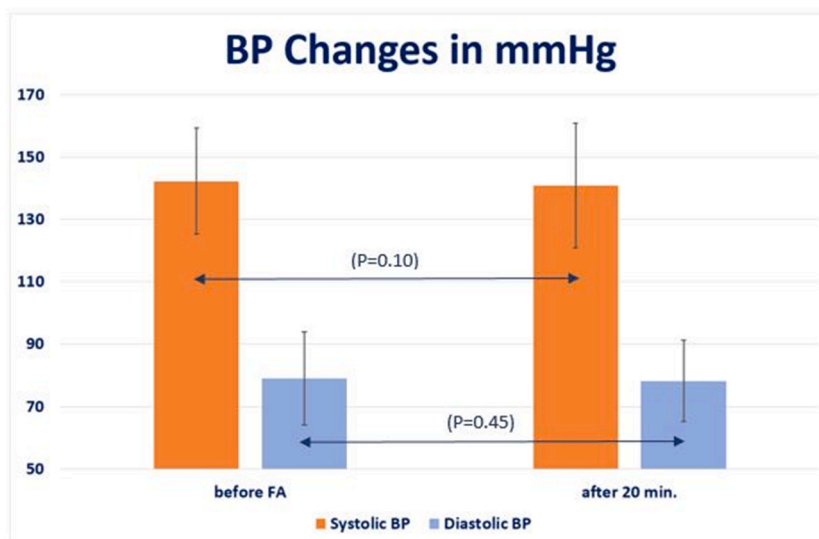


Fig. 1. Changes of blood pressure (BP) before and 20 min after fluorescein angiography (FA) for all patients.

Sixteen percent ($n = 103$ patients) had acute elevation of systolic BP (>10 mmHg). The mean systolic BP changed in this group from 142.8 ± 17 to 161.8 ± 19 after 20 min ($p = 0.001$). Patients in this group were significantly older (73.8 ± 12 y/o) compared to the rest of the patients (67.5 ± 15 y/o) ($p = 0.001$).

The rate of patients with heart failure, diabetes mellitus, history of cerebrovascular accident, smoking, coronary artery disease, atrial fibrillation and arterial hypertension in this group showed no statistical significant difference compared to the rest of the patients ($p > 0.05$).

The rate of patients with chronic renal failure was significantly higher in this group (16.4 %, $n = 15$ patients) compared to the rest of the patients (7.8 %, $n = 42$ patients) ($p = 0.01$) (Table 1).

In multi-variable Cox regression analysis, presence of chronic renal failure but not advanced age, was found to be predictors of acute elevation of BP after FA.

3.3. Patients with chronic renal failure

In patients with chronic renal failure ($n = 57$), the mean systolic baseline BP changed from 133.7 ± 17 to 152.3 ± 16 after 20 min ($p = 0.001$). The diagnosis of renal failure in this study was primarily confirmed by a nephrologist for each patient, and we reviewed the last GFR value to determine the current stage. The distribution of patients with renal failure according to chronic renal failure stages [16] is shown in Table 2.

Other side effects:

- Nausea: 3.3 % ($n = 11$ patients)
- Fatigue: 1.4 % ($n = 5$ patients)
- Dizziness: 1.7 % ($n = 6$ patients)
- Anaphylactic reactions: 0 % ($n = 0$ patients)

Table 2

The distribution of patients with renal failure according to chronic renal failure stages [16].

Stage	GFR (mL/min per 1.73 m ²)	other patients ($n = 533$)	systolic BP (>10 mmHg) ($n = 103$)	Total
G1	≥ 90	37 (6.90 %)	10 (9.70 %)	47
G2	60–89	0	2 (1.96 %)	2
G3a	45–59	0	1 (0.98 %)	1
G3b	30–44	1 (0.10 %)	0	1
G4	15–29	4 (0.80 %)	1 (0.98 %)	5
G5	<15	0	1 (0.98 %)	1
Total		42 (7.8 %)	15 (14.6 %)	57

BP: Blood pressure, GFR: Glomerular filtration rate.

4. Discussion

This present prospective analysis was performed to examine the effect of FA on BP and showed that FA is a safe procedure in terms of BP changes. However, we found that chronic renal failure could be considered as predictive factor for acute elevation of systolic BP after this procedure.

Following its introduction in 1961, FA has been widely used for the diagnosis of retinal diseases. Since then, numerous side effects of FA have been reported in the literature, of which Kwiterovich et al., in 1991, reported an overall side effect rate of 4.8 % among 2025 patients, including nausea (2.9 %), flushing (0.5 %), and syncope (0.2 %) [17]. Furthermore, a large-scale systematic review analyzed the results of 78 articles reporting side effects of FA from 1961 to 2017. The overall frequency of side effects ranged from 0.083 to 21.69 %, divided into mild (1.24–17.65 %), moderate (0.2–6%), and severe (0.04–0.59 %). Fatalities ranged from 1:100,000 to 1:220,000 [18].

Together, these data could support the result of our study, in which a total of about 6 % side effects occurred, ranging from mild to moderate (nausea 3.3 %, fatigue 1.4 %, and dizziness: 1.7 %), without any serious or fatal side effect.

Cardiovascular side effects have neither been widely reported nor discussed. In 1979, authors [19] described a possible effect of fluorescein dye on the heart. Concomitantly, numerous cardiac side effects have been reported after FA, including hypertensive crises and myocardial infarction. For example, Deglin reported the first case of acute myocardial infarction with hypertensive crisis after FA in 1977 [20]. Similarly, Karhunen reported 3 cases of myocardial infarction in 1986, with one case of collapse during FA showing asystole on electrocardiogram [21]. The first case of acute myocardial infarction documented by autopsy was reported in 1993 by Ascaso et al. [22].

Changes in BP values during or after FA have been controversial in the literature.

- Some studies focused on hypotension after FA and questioned whether it could be a consequence of the anaphylaxis that fluorescein can induce [23]. Several pathophysiologic mechanisms could be responsible for this reaction, including, vasovagal response, medication-induced immediate hypersensitivity and nonallergic histamine release [24,25]. However, the exact mechanism is still unknown and could be multifaceted. In several studies, IgE-mediated anaphylaxis to fluorescein has been mentioned as a main mechanism, although this has not yet been demonstrated with CD-sens.
- On the other hand, some cases of **hypertensive** crises during or after FA have been reported in the literature [20,21]. However, all of these were just **case reports without clear mechanisms** for such an occurrence.
- To our knowledge, the only study, which tried to investigate the effects of fluorescein on elderly patients with hypertension, in same the context of our study was (Musa et al., 2006). This was a retrospective study of 358 elderly patients in whom no serious cardiovascular complications were noted. There was **no significant change in mean systolic and diastolic BP** before and 20 min after FA [12]. This could correlate with the overall change in mean systolic and diastolic BP before and after FA in our results. However, our study focused on the patients who had an acute elevation in systolic BP (>10 mmHg).

Multiple data showed an increased risk of mortality and cardiovascular events for every 10–20 mmHg increase in BP [26]. We decided to use the cut-off value of 10 mmHg to define patients at risk. Furthermore, for the same methodological/statistical reasons as Aiyer et al. [27], who defined an acute elevation between 10 and 20 mmHg, we assumed a relevant elevation to be 10 mmHg systolic BP.

According to this assessment, 16 % of all patients in our study had an acute elevation in systolic BP 20 min after FA. This acute elevation in systolic BP could be caused by the sympathetic or vasospastic response to fluorescein as a pathophysiological mechanism [25].

Moreover, we tried to identify a predictive factor that could be responsible for this acute elevation. The percentage of patients with heart failure, diabetes mellitus, history of cerebrovascular accident, smoking, coronary artery disease, atrial fibrillation, and arterial hypertension was statistically similar in this group of patients compared to the rest of patients. However, the patients with acute BP elevation were significantly older (73 ± 12 vs 67 ± 15 , $p = 0.001$) and had a higher prevalence of chronic renal failure (42/7.8 % vs 15/14.6 %, $p = 0.01$).

It is well known that systolic BP increases steadily with age, which could be due to a general process of increasing arterial rigidity [28,29]. On the other hand, a highly graded relationship between systolic and diastolic BP and end-stage renal failure has been established [30].

In this study, Chronic kidney failure was defined as the presence of abnormalities of kidney structure or function (ie, abnormal albuminuria or estimated glomerular filtration rate [eGFR]) less than 60 ml/min/1.73 mm², persisting for 3 months or more, irrespective of the cause. This information was determined from the medical record or based on the recent blood values [31].

Furthermore, an increase in short-term systolic BP variability has been associated with the progression of renal failure [32]. This could be due to various pathophysiological mechanisms that are common in patients with renal failure, such as hyperactivity of the sympathetic nervous system, fluctuations in the renin-angiotensin-aldosterone system and arterial rigidity, as well as possible drug side effects [33–35].

The results of our analysis suggest that FA is a safe procedure with no acute effect on BP. Additionally; this study highlights the role of chronic renal failure as a predictive factor for acute elevation of systolic BP due to FA. Consequently, patients with chronic renal failure should have their blood pressure closely monitored, which clearly correlates with the fact that renal failure is closely related to hypertension. However, it must be mentioned that diagnosed hypertension alone was not a predictive factor for acute elevation of systolic blood pressure due to FA in our study, confirming once again that patients with chronic renal failure are a special patient

group, even in comparison to those with hypertension alone, and require special attention regarding blood pressure changes.

However, there are limitations of this study that need to be recognized:

- This study includes a moderate number of patients.
- BP was not measured continuously and patients were not masked.
- The normal adult dosage of fluorescein sodium dye is 500 mg and is usually packaged in doses of 5 ml of 10 % or 2 ml of 25 %. The use of a half dosage of 2.5 ml of 10 % fluorescein is a relatively common practice that has been mentioned in some previous clinical reports and even compared with the use of the normal dosage to demonstrate any reduction in the frequency and severity of side effects, leading to the conclusion that a reduction in the dosage dose did not significantly reduce the frequency of side effects [36]. Nevertheless, the use of a low fluorescein dosage (2.5 ml) instead of the normal dosage (5 ml) must be considered as a limitation in this study, as this dosage may cause fewer adverse events, including an increase in BP.

Therefore, further studies using more advanced methods are required to confirm our findings.

5. Conclusions

This study demonstrated that fluorescein angiography is a relatively safe procedure relating to blood pressure changes. However, chronic renal failure could be considered as predictive factor for acute elevation of systolic blood pressure due to this procedure and these patients should be monitored closely.

Credit author statement

Alaa Din Abdin: Conceptualization, Methodology, Writing – original draft, Marie Hammerschmidt: Data curation, Investigation, Amine Maamri: Conceptualization, Cristian Munteanu: Software, Formal analysis, Bernhard Haring: Visualization, Michael Böhm and Berthold Seitz: Supervision, Amr Abdin: Conceptualization, Validation, All authors: Writing – review & editing.

Ethical approval

This study was approved by the Ethics Committee of the Medical Association of Saarland, Germany (No. 129/21). All procedures performed in studies involving human participants were in accordance with the ethical standards of the institutional and/or national research committee and with the 1964 Helsinki declaration and its later amendments or comparable ethical standards. This article does not contain any studies with animals performed by any of the authors.

Funding

No funding was received for this research.

Commercial relationships disclosures

None.

Data availability statement

The datasets used and/or analyzed during the current study are available from the corresponding author on reasonable request.

Declaration of competing interest

The authors declare that they have no known competing financial interests or personal relationships that could have appeared to influence the work reported in this paper.

Appendix A. Supplementary data

Supplementary data to this article can be found online at <https://doi.org/10.1016/j.heliyon.2023.e22700>.

References

- [1] H.R. Novotny, D.L. Alvis, A method of photographing fluorescence in circulating blood in the human retina, *Circulation* 24 (1) (1961) 82–86, <https://doi.org/10.1161/01.cir.24.1.82>. PMID: 13729802.
- [2] J.W. Berkow, R.W. Flower, D.H. Orth, J.S. Kelley, *Fluorescein and indocyanine green angiography: technique and interpretation*, in: *Ophthalmology Monograph* 5, second ed., American Academy of Ophthalmology, San Francisco, 1997.

- [3] S. Dithmar, F.G. Holz, *[Fluorescence Angiography in Ophthalmology]*, Springer Berlin Heidelberg, 2008, pp. 2–3.
- [4] A.N. Kollias, M.W. Ulbig, Diabetic retinopathy: early diagnosis and effective treatment, *Dtsch Arztebl Int* 107 (5) (2010) 75–83, <https://doi.org/10.3238/arztebl.2010.0075>. PMID: 20186318.
- [5] H. Dobbstein, A.W. Weinberger, S. Wolf, [Fluorescein angiography in age-related macular degeneration], *Ophthalmologie* 95 (8) (1998) 581–596, <https://doi.org/10.1007/s003470050320>. PMID: 9782738.
- [6] O. Arend, A. Remky, U. Solbach, A. Harris, S. Wolf, M. Reim, [Digital fluorescein angiography in follow-up of the clinical course in therapy of patients with central vein occlusion and cystoid macular edema], *Klin Monbl Augenheilkd* 209 (2–3) (1996) 163–170, <https://doi.org/10.1055/s-2008-1035298>. PMID: 8992079. German.
- [7] T. Hirsch, A. Remky, N. Plange, M. Kaup, [Quantification of fluorescein angiography in patients with non-arteritic anterior ischemic optic neuropathy], *Ophthalmologie* 108 (8) (2011) 728–732, <https://doi.org/10.1007/s00347-011-2387-9>. PMID: 21681366.
- [8] M. Inoue, J.J. Jung, C. Balaratnasingam, K.K. Dansingani, E. Dhrami-Gavazi, M. Suzuki, T.E. de Carlo, A. Shahlaee, M.A. Klufas, A. El Maftouhi, J.S. Duker, A. C. Ho, M.Q. Maftouhi, D. Sarraf, K.B. Freund, COFT-1 Study Group A comparison between optical coherence tomography angiography and fluorescein angiography for the imaging of type 1 neovascularization, *Invest. Ophthalmol. Vis. Sci.* 57 (9) (2016) OCT314–O323, <https://doi.org/10.1167/iovs.15-18900>. PMID: 27409488.
- [9] J.L. Morrison, L.A. Hodgson, L.L. Lim, S. Al-Qureshi, Diabetic retinopathy in pregnancy: a review, *Clin. Exp. Ophthalmol.* 44 (4) (2016) 321–334, <https://doi.org/10.1111/ceo.12760>. PMID: 27062093.
- [10] Novartis Pharmaceuticals Australia Pty Limited, Product information fluorescein* (fluorescein injection) 10%, Available from: <https://www.tga.gov.au/artg/artg-id-124267>, 2015.
- [11] L.S. Halperin, R.J. Olk, G. Soubrane, G. Coscas, Safety of fluorescein angiography during pregnancy, *Am. J. Ophthalmol.* 109 (5) (1990) 563–566, [https://doi.org/10.1016/s0002-9394\(14\)70686-5](https://doi.org/10.1016/s0002-9394(14)70686-5). PMID: 1970705.
- [12] F. Musa, W.J. Muen, R. Hancock, D. Clark, Adverse effects of fluorescein angiography in hypertensive and elderly patients, *Acta Ophthalmol. Scand.* 84 (6) (2006) 740–742, <https://doi.org/10.1111/j.1600-0420.2006.00728.x>. PMID: 17083530.
- [13] D.G. Beevers, G.Y. Lip, E.T. O'Brien, *ABC of Hypertension*, John Wiley & Sons, 2014.
- [14] B. Williams, G. Mancia, W. Spiering, E. Agabiti Rosei, M. Azizi, M. Burnier, D.L. Clement, A. Coca, G. de Simone, A. Dominiczak, T. Kahan, F. Mahfoud, J. Redon, L. Ruilope, A. Zanchetti, M. Kerins, S.E. Kjeldsen, R. Kreutz, S. Laurent, G.Y.H. Lip, R. McManus, K. Narkiewicz, F. Ruschitzka, R.E. Schmieder, E. Shlyakhto, C. Tsioufis, V. Aboyans, I. Desormais, ESC Scientific Document Group, 2018 ESC/ESH Guidelines for the management of arterial hypertension, *Eur. Heart J.* 39 (33) (2018) 3021–3104, <https://doi.org/10.1093/eurheartj/ehy339>.
- [15] J. Peat, B. Barton, E. Elliott, *Statistics Workbook for Evidence-Based Health Care*, John Wiley & Sons, 2009.
- [16] P.E. Stevens, A. Levin, *Kidney Disease, Improving Global Outcomes Chronic Kidney Disease Guideline Development Work Group Members. Evaluation and management of chronic kidney disease: synopsis of the kidney disease: improving global outcomes 2012 clinical practice guideline*, *Ann. Intern. Med.* 158 (11) (2013) 825–830.
- [17] K.A. Kwitterovich, M.G. Maguire, R.P. Murphy, A.P. Schachat, N.M. Bressler, S.B. Bressler, S.L. Fine, Frequency of adverse systemic reactions after fluorescein angiography. Results of a prospective study, *Ophthalmology* 98 (7) (1991) 1139–1142, [https://doi.org/10.1016/s0161-6420\(91\)32165-1](https://doi.org/10.1016/s0161-6420(91)32165-1). PMID: 1891225.
- [18] I.S. Kornblau, J.F. El-Annan, Adverse reactions to fluorescein angiography: a comprehensive review of the literature, *Surv. Ophthalmol.* 64 (5) (2019) 679–693, <https://doi.org/10.1016/j.survophthal.2019.02.004>. PMID: 30772364.
- [19] E.E. Cunningham, V. Balu, Cardiac arrest following fluorescein angiography, *JAMA* 242 (22) (1979) 2431. PMID: 490857.
- [20] S.M. Deglin, E.A. Deglin, E.K. Chung, Acute myocardial infarction following fluorescein angiography, *Heart Lung* 6 (3) (1977) 505–509. PMID: 585685.
- [21] U. Karhunen, C. Raitta, R. Kala, Adverse reactions to fluorescein angiography, *Acta Ophthalmol.* 64 (3) (1986) 282–286, <https://doi.org/10.1111/j.1755-3768.1986.tb06919.x>. PMID: 2944349.
- [22] F.J. Ascaso, M.T. Tiestos, J. Navales, F. Iturbe, A. Palomar, J.I. Ayala, Fatal acute myocardial infarction after intravenous fluorescein angiography, *Retina* 13 (3) (1993) 238–239, <https://doi.org/10.1097/00006982-199313030-00009>. PMID: 8235107.
- [23] J.E. Heffner, Reactions to fluorescein, *JAMA* 243 (20) (1980) 2029–2030. PMID: 7373739.
- [24] A. Breidablik, G.H. De Pater, C. Walther, A. Nopp, A.B. Guttormsen, Intravenous fluorescein as a cause of immunoglobulin E-mediated anaphylactic shock, *Acta Anaesthesiol. Scand.* 56 (8) (2012) 1066–1068, <https://doi.org/10.1111/j.1399-6576.2012.02732.x>. PMID: 22762373.
- [25] S.O. Ha, D.Y. Kim, C.H. Sohn, K.S. Lim, Anaphylaxis caused by intravenous fluorescein: clinical characteristics and review of literature, *Intern Emerg Med* 9 (3) (2014) 325–330, <https://doi.org/10.1007/s11739-013-1019-6>. PMID: 24293212.
- [26] National high blood pressure education program, in: *The Seventh Report of the Joint National Committee on Prevention, Detection, Evaluation, and Treatment of High Blood Pressure*, National Heart, Lung, and Blood Institute (US), Bethesda (MD), 2004. Blood pressure and cardiovascular risk. Available from: <http://www.nhlbi.nih.gov/health-topics/high-blood-pressure>.
- [27] A.N. Aiyer, K.E. Kip, S.R. Mulukutla, O.C. Marroquin, L. Hipps Jr., S.E. Reis, Predictors of significant short-term increases in blood pressure in a community-based population, *Am. J. Med.* 120 (11) (2007) 960–967, <https://doi.org/10.1016/j.amjmed.2007.06.021>. PMID: 17976423.
- [28] V.L. Burt, P. Whelton, E.J. Rocella, C. Brown, J.A. Cutler, M. Higgins, et al., Prevalence of hypertension in the US adult population. Results from the third national health and nutrition examination survey, 1988–1991, *Hypertension* 25 (3) (1995) 305–313, <https://doi.org/10.1161/01.hyp.25.3.305>. PMID: 7875754.
- [29] M. O'Rourke, Arterial stiffness, systolic blood pressure, and logical treatment of arterial hypertension, *Hypertension* 15 (4) (1990) 339–347, <https://doi.org/10.1161/01.hyp.15.4.339>. PMID: 2180816.
- [30] M.J. Klag, P.K. Whelton, B.L. Randall, J.D. Neaton, F.L. Brancati, C.E. Ford, et al., Blood pressure and end-stage renal disease in men, *N. Engl. J. Med.* 334 (1) (1996) 13–18, <https://doi.org/10.1056/NEJM199601043340103>. PMID: 7494564.
- [31] Chapter 1: definition and classification of CKD, *Kidney Int. Suppl.* 3 (1) (2011) 19–62, 2013 Jan.
- [32] P.A. Sarafidis, L.M. Ruilope, C. Loutradis, M. Gorostidi, A. de la Sierra, J.J. de la Cruz, et al., Blood pressure variability increases with advancing chronic kidney disease stage: a cross-sectional analysis of 16 546 hypertensive patients, *J. Hypertens.* 36 (5) (2018) 1076–1085, <https://doi.org/10.1097/HJH.0000000000001670>. PMID: 29465710.
- [33] J. Neumann, G. Ligtenberg, Klein II, H.A. Koomans, P.J. Blankestijn, Sympathetic hyperactivity in chronic kidney disease: pathogenesis, clinical relevance, and treatment, *Kidney Int.* 65 (5) (2004) 1568–1576, <https://doi.org/10.1111/j.1523-1755.2004.00552.x>. PMID: 15086894.
- [34] P.A. Sarafidis, L.M. Ruilope, Aggressive blood pressure reduction and renin-angiotensin system blockade in chronic kidney disease: time for re-evaluation? *Kidney Int.* 85 (3) (2014) 536–546, <https://doi.org/10.1038/ki.2013.355>. PMID: 24048382.
- [35] G. Parati, J.E. Ochoa, G. Bilo, R. Agarwal, A. Covic, F.W. Dekker, et al., Hypertension in chronic kidney disease part 2: role of ambulatory and home blood pressure monitoring for assessing alterations in blood pressure variability and blood pressure profiles, *Hypertension* 67 (6) (2016) 1102–1110, <https://doi.org/10.1161/HYPERTENSIONAHA.115.06896>. PMID: 27141057.
- [36] K. Xu, V. Tzankova, C. Li, S. Sharma, Intravenous fluorescein angiography-associated adverse reactions, *Can. J. Ophthalmol.* 51 (5) (2016) 321–325, <https://doi.org/10.1016/j.cjco.2016.03.015>. PMID: 27769320.