


Cite this article as: Abeln KB, Ehrlich T, Souko I, Brenner F, Schäfers H-J. Autograft reoperations after the Ross procedure. Eur J Cardiothorac Surg 2023; doi:10.1093/ejcts/ezad117.

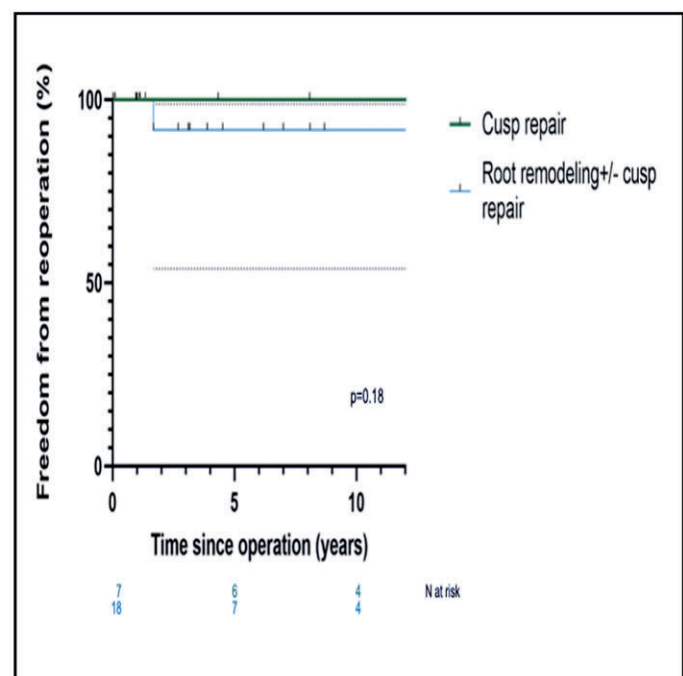
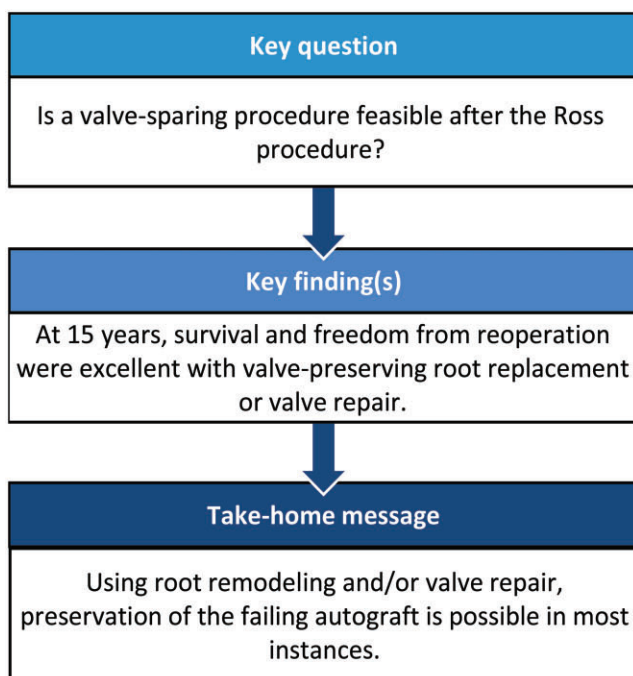
Autograft reoperations after the Ross procedure

Karen B. Abeln , Tristan Ehrlich , Idriss Souko, Friederike Brenner and Hans-Joachim Schäfers *

Department of Thoracic and Cardiovascular Surgery, Saarland University Medical Center, Homburg/Saar, Germany

* Corresponding author. Department of Thoracic and Cardiovascular Surgery, Saarland University Medical Center, Kirrbergerstraße 100, 66424 Homburg/Saar, Germany. Tel: +49-6841-1632000; fax: +49-6841-1632005; e-mail: h-j.schaefers@uks.eu (H-J. Schäfers).

Received 20 October 2022; received in revised form 13 March 2023; accepted 26 March 2023



Abstract

OBJECTIVES: After a Ross procedure, autograft failure can occur. At reoperation, repair of the autograft preserves the advantages of the Ross procedure. The aim of this retrospective study was to assess mid-term results after reoperation of a failed autograft.

METHODS: Between 1997 and 2022, 30 consecutive patients (83% male; age 41 ± 11 years) underwent autograft reintervention between 60 days and 24 years (median 10 years) after a Ross procedure. The initial technique varied, full-root replacement ($n = 25$) being the most frequent. The indication for reoperation was isolated autograft regurgitation ($n = 7$), root dilatation (>43 mm) with ($n = 17$) or without ($n = 2$) autograft regurgitation, mixed dysfunction ($n = 2$) and endocarditis ($n = 2$). In 4 instances, the valve was replaced by valve ($n = 1$) or combined valve and root replacement ($n = 3$). Valve-sparing procedures consisted of isolated valve repair ($n = 7$) or root replacement ($n = 19$), and tubular aortic replacement. Cusp repair was performed in all but 2. Mean follow-up was 5.4 ± 6 years (35 days to 24 years).

RESULTS: Mean cross-clamp and perfusion times were 74 ± 26 and 132 ± 64 min. There were 2 perioperative deaths (7%; both valve replacement) and 2 patients died late (32 days to 1.2 years postoperatively). Freedom from cardiac death at 10 years was 96% after valve repair and 50% after replacement. Two patients required reoperation (1.68 and 16 years) following repair. One underwent valve replacement

Presented at the EACTS Annual Meeting 2021, Barcelona, Spain, 15 October 2021.

for cusp perforation, the other, root remodelling for dilatation. Freedom from autograft reintervention at 15 years was 95%.

CONCLUSIONS: Autograft reoperations after the Ross procedure can be performed as valve-sparing operations in the majority of cases. With valve-sparing, long-term survival and freedom from reoperation are excellent.

Keywords: Ross procedure • Pulmonary autograft dilatation • Valve-sparing procedure • Autograft failure

ABBREVIATION

AR Autograft regurgitation

INTRODUCTION

Aortic valve replacement with a pulmonary autograft offers patients a living valve substitute that provides excellent haemodynamics, freedom from long-term use of anticoagulation, minimal valve-related complications and the ability to grow. The procedure is preferably employed in children and younger patients who have a long life expectancy, exposing them to a prolonged period of cardiac- and prosthesis-related complications. Studies from specialized centres have reported excellent results [1–7].

Nevertheless, failure of the autograft may occur over time; in addition, degeneration of the right ventricular conduit may develop. Autograft failure has been found to follow 2 different pathways. Early presentation is mostly related to primary valve failure (i.e. cusp prolapse); late failure is often associated with autograft root dilatation [8] and tends to develop gradually, with the highest progression in the first 5 years [7–9].

Thus, there is an inherent risk of reintervention after the Ross procedure. The autograft is often replaced with a stented valve prosthesis [10–12], either by replacing the valve or autograft root and valve as composite replacement [10–12]. This, however, exposes the patient to the potential complications that were to be avoided at the time of the initial procedure. The development of valve-sparing root replacement and aortic valve repair [13–17] represents an alternative approach, potentially preserving the advantages of the Ross procedure. This form of surgery has, so far, been used in selected patients (11–47%) [11, 18]. Only in 2 studies was valve preservation used in the majority of reoperative procedures [16, 19], and in only one study, published by the Brussels group [5, 16], was isolated valve repair performed. In their experience, however, isolated cusp repair was associated with suboptimal durability.

Concerns exist regarding the complexity of valve preservation at reoperation [3, 12, 20]. These valve-sparing procedures have been associated with increased perioperative morbidity and not always achieved durable repair results [12, 16, 21]. This may be due to the fact that cusp prolapse may also contribute to autograft failure apart from its dilatation. Thus, a combined root and cusp repair approach is necessary to restore autograft form and function to normal. Interestingly, isolated cusp repair has been associated with high rates of recurrent autograft regurgitation (AR) [16, 21]. There is currently limited information regarding the details of autograft failure and in particular the frequency of cusp prolapse.

Based on our experience with concomitant valve-sparing root replacement and cusp repair, we have applied the principles of

aortic valve repair to all failing autografts over the past 20 years [22]. The aim of this study was to analyse the mechanisms leading to autograft failure in detail and to assess the early and late results of reoperations of a failed autograft.

PATIENTS AND METHODS

Ethical statement

The investigation was approved by the regional ethics committee (Saarland Regional Ethics Committee, CEP 203/19), and individual patient consent was waived for the analysis and publication in anonymized fashion.

Patients

Between December 1997 and June 2022, 30 consecutive patients (83% male; mean age 41 ± 11 years) underwent autograft reintervention after a Ross procedure after a median of 10 (4–13) years (Table 1). These patients were the subject of the current study. Overall, 280 Ross procedures were performed at our institution; of those, 16 (6%) underwent autograft reoperation.

The initial operation had been performed 60 days to 24 years prior to the index procedure. Fifteen patients underwent the Ross procedure at our institution and 15 in other institutions. At the time of the initial operation, patient age ranged from 24 to 39 years (31 ± 11 years). The initial technique had been subcoronary implantation ($n = 2$), full-root replacement ($n = 25$) or cylinder inclusion ($n = 3$). Any form of annular or sinus stabilization had been used in 13 cases (43%) as part of the initial Ross procedure (suture annuloplasty, $n = 5$; sinus stabilization with native aortic wall remnants, $n = 7$; sinotubular junction stabilization with a Dacron strip, $n = 2$) (Table 1).

The original aortic valve morphology was unicuspid in 8 (27%), bicuspid in 11 (37%), tricuspid in 6 (20%) and quadricuspid in 1 (3%) individual. Four patients had undergone valve replacement prior to the Ross procedure and the original morphology could not be determined. Eleven patients (37%) had undergone at least 1 cardiac operation prior to the Ross procedure, 4 (13%) of which had undergone between 2 and 3 operations.

At the time of reoperation, the primary indication was isolated AR ($n = 7$) and root dilatation (>43 mm) with ($n = 17$) or without ($n = 2$) AR. Endocarditis was suspected in 7 patients ($n = 7$), which was confirmed in 2 ($n = 2$), in both cases due to intravenous drug use. Two patients had combined autograft stenosis and regurgitation ($n = 2$; Table 2).

Autograft dilatation ≥ 43 mm was present in 19 (63%) cases. Of these, 9 (30%) initially underwent the Ross procedure as full root replacement without external stabilization. Dilatation of the ascending aorta (involving the sinotubular junction) was present in 5 (17%) cases.

Table 1: Baseline characteristics

Patient characteristics	N = 30
Male gender, n (%)	25 (83)
Age, median (IQR)	42 (33–48)
Initial Ross procedure, n (%)	
Homburg	15 (50)
Other institutions	15 (50)
Technique, n (%)	
Full root replacement	25 (83)
Modified cylinder inclusion	3 (10)
Subcoronary	2 (7)
Cardiovascular risk factors, n (%)	
Arterial hypertension	19 (63)
Coronary artery disease	1 (3)
Smoker	3 (10)
Intravenous drug abuse	3 (10)
Initial valve morphology, n (%)	
Unicuspid	8 (27)
Bicuspid	11 (37)
Tricuspid	6 (20)
Quadricuspid	1 (3)
Unclear	4 (13)
Aortic regurgitation grade, n (%)	
I	4 (13)
II	7 (23)
III or IV	17 (57)
Autograft root diameter, median (IQR) mm	
Annulus	28 (25–30)
Sinus	40 (34–49)
STJ	39 (29–43)
LVEF (%), mean ± SD	53 ± 13
LVEF <50%, n (%)	8 (29)
LVEDd (mm), mean ± SD	60 ± 11
EuroScore II, mean ± SD	6.2 ± 5.9

IQR: interquartile range; LVEDd: left ventricular end-diastolic diameter; LVEF: left ventricular ejection fraction; SD: standard deviation; STJ: sinotubular junction.

Table 2: Patterns of pulmonary autograft failure according to implantation technique

N = 30 (%)	Full root n = 25	Others n = 5
Aortic dilatation (≥40 mm) before Ross, n (%)		
Aortic root	7 (28)	1 (20)
Ascending aorta	3 (12)	1 (20)
Isolated AR before Ross	9 (36)	2 (40)
Ascending aortic replacement at Ross, n (%)	4 (16)	1 (20)
Autograft regurgitation at discharge (≥2), n (%)	1 (4)	0 (0)
Time between Ross and redo (years), mean ± SD	10 ± 6	8 ± 5
Indication for reoperation, n (%)		
Autograft dilatation (≥43 mm) ± AR	18 (76)	1 (20)
Isolated autograft regurgitation	6 (20)	1 (20)
Active endocarditis	1 (4)	1 (20)
Combined AR/AS	0 (0)	2 (40)
Pathology at reoperation, n (%)		
Cusp prolapse	13 (52)	3 (60)
Cusp perforation	4 (16)	1 (20)
Perivalvular cavity (sterile)	3 (12)	2 (40)
Perivalvular abscess (endocarditis)	1 (4)	1 (20)
Degeneration due to SLE	0 (0)	2 (40)

AR: aortic regurgitation; AS: aortic stenosis; SD: standard deviation; SLE: systemic lupus erythematosus.

Median and mean follow-up were 3.3 (0.8–8.1) years and 5.4 ± 6 years. Follow-up was 98% complete (160 patient-years).

Surgical technique

Intraoperative transoesophageal echocardiography was performed for assessment of autograft root dimensions and indirect evidence of cusp pathology. The surgical technique depended on the aortic and cusp pathology encountered, including valve-sparing root replacement, cusp repair and suture annuloplasty as needed. Autograft diameters triggered specific procedures on the aortic root. The need for additional cusp repair was determined by intraoperative presence of perforation or prolapse. The need for concomitant replacement of the right ventricular conduit was dictated by moderate to severe dysfunction of the pulmonary valve substitute ($n = 4$) (Table 3).

Root remodelling was the procedure of choice for valve-sparing root replacement and was performed when sinus diameters exceeded 43 mm ($n = 18$). Aortic valve reimplantation was performed in one instance in a patient with an elongated outflow tract. For correction of sinotubular dilatation (>35 mm)—in all instances in conjunction with tubular aortic aneurysm—tubular aortic replacement was performed as sinotubular remodelling. If annular size exceeded 26 mm, a suture annuloplasty was added.

The chest was reopened by median sternotomy and the patient connected to cardiopulmonary bypass by aortic and right atrial cannulation. The aorta was cross-clamped and transected 5–10 mm above the commissures; cardioplegia was given directly into the coronary ostia. The root was dissected towards the annular plane and all foreign material was removed. The valve was systematically assessed for its geometry and additional cusp lesions. Geometric cusp height [23] was measured, and valve preservation was only pursued if geometric height was at least 19 mm in all cusps. If root dimensions were preserved, effective height of each cusp was determined [23]. Cusp prolapse was

Table 3: Perioperative data

	N = 30
Surgical technique, n (%)	
Root remodelling ± valve repair	18 (60)
Root reimplantation + valve repair	1 (3)
Isolated valve repair	7 (23)
Mechanical root replacement	3 (10)
Biological valve replacement	1 (3)
Annular support, n (%)	
PTFE suture	18 (60)
Concomitant procedure, n (%)	
RVPA conduit replacement	4 (13)
Hemi-arch using circulatory arrest	3 (10)
Mitral valve repair	3 (10)
Tricuspid valve repair	2 (7)
Coronary artery bypass	1 (3)
Perfusion time (min), median (IQR)	116 (99–137)
Myocardial ischaemia (min), median (IQR)	79 (56–89)
LOS, median (IQR)	7 (6–10)
Perioperative complications, n (%)	
Bleeding	0 (0)
Permanent pacemaker implantation	1 (3)

IQR: interquartile range; LOS: length of stay; PTFE: polytetrafluoroethylene; RV-PA: right ventricle to the pulmonary artery.

defined as effective height <9 mm and corrected by central plication until the cusps measured 9–10 mm ($n=16$). In cases where aortic or root replacement was necessary, determination of effective height was done after completion of the aortic procedure.

For root replacement, the sinus wall was excised and the coronary buttons were mobilized, [14, 24]. Graft size was chosen according to the patient's body surface area [14]. For sinotubular junction remodelling, care was taken to anastomose the vascular graft to the root at commissural level. An external annuloplasty was added, if required, using an expanded polytetrafluoroethylene suture (Gore-TexCV-0; W.L. Gore & Assoc., Munich, Germany) (Table 3). The suture was tied around a Hegar dilator (21–25 mm, depending on body surface area).

Cusp perforations and cavities were closed with a pericardial patch ($n=6$; Autotissue, Berlin, Germany). Cusp prolapse was corrected by central plication ($n=16$). In one instance, a false aneurysm at the proximal suture line of the autograft was closed directly, in the other with a pericardial patch. If the pre-operative echocardiography showed relevant degeneration of the pulmonary conduit, it was replaced with a pulmonary homograft ($n=4$).

Follow-up

All patients were seen regularly by their referring cardiologists or in our clinic. Echocardiograms from our institution and referring cardiologists were reviewed. In addition, the patients were contacted directly to determine their current functional status. The cause of death was determined by review of the hospital chart or information from the primary care physician.

Statistical analyses

This is a retrospective analysis of prospectively collected data. Descriptive statistics are presented as mean (\pm standard deviation) or median (interquartile range), and the Mann-Whitney *U*-test or *t*-test were used for between-group comparisons. The 'Percentage Method' was used for estimating the follow-up rate.

The date of first occurrence of AR \geq II was recorded for time-to-event calculation. Categorical variables were expressed as frequencies (%). Time-dependent data were analysed using the Kaplan-Meier method. Differences were assessed using the log-rank test. Survival and freedom from reintervention and AR were calculated at 8, 10 and 15 years. All statistical tests were 2-sided and *P*-values <0.05 were considered statistically significant for all analyses. All statistical analyses were performed using statistical package SPSS version 28.0 (IBM Corp. Released 2021. IBM SPSS Statistics for Macintosh, Version 28.0. Armonk, NY, USA: IBM Corp).

Sinus diameters were analysed as absolute diameters and a root diameter \geq 40 mm was considered dilated. Pulmonary valve stenosis was defined as mild (maximum gradient <30 mmHg), moderate (maximum gradient 30–60 mmHg) and severe (maximum >60 mmHg).

'Early' events were defined as any event occurring within 30 days postoperatively.

Primary endpoints were survival and freedom from autograft reintervention; secondary endpoints were freedom from AR, and aortic root dilatation.

RESULTS

Early

The cohort was divided into 2 groups: valve replacement ($n=4$) (degenerated autograft $n=2$, root abscess $n=2$) and valve-sparing procedure ($n=26$). Patients with root replacement and cusp repair ($n=19$) were further compared to patients with isolated cusp repair ($n=7$). Survival, freedom from reoperation and AR, and aortic root dimensions were compared between the groups.

Eleven patients (37%) had a concomitant procedure, most commonly right ventricular conduit replacement ($n=4$) and hemi-arch replacement ($n=3$). Median myocardial ischaemia and extracorporeal perfusion times were 79 (56–89) and 116 (99–137) min, respectively.

There were 4 deaths overall; 2 patients died early. One patient underwent mechanical valve replacement for autograft failure following previous biological valve replacement; she died from uncontrollable coagulopathy due to heparin-induced thrombocytopenia. The second patient had reduced left ventricular function and developed atrial fibrillation refractory to treatment with low output syndrome; he died from multiorgan failure.

There was no myocardial infarction or neurological complication. One patient who underwent valve replacement required a permanent pacemaker implantation.

Myocardial ischaemia times were similar for valve-sparing (73 ± 28 min) and valve replacement (61 ± 22 min; $P=0.92$), valve-sparing procedures had shorter perfusion times (valve-sparing: 110 ± 73 min, conventional valve replacement: 157 ± 116 min; $P=0.02$; Table 3).

Cusp pathology

Cusp prolapse was found in 16 instances. It was present in 13 of 19 cases with autograft dilatation (all after full-root replacement) and in 3 of 11 with preserved root dimensions. Cusp perforation without evidence of active infection was found in 5 cases. Cusp retraction was present in 2 instances, in 1 case in the presence of systemic lupus erythematosus.

Other root pathology

Perivalvular abscess formation with positive PCR (polymerase chain reaction) studies for endocarditis was encountered in 2 cases. In 5 additional patients, a perivalvular cavity was found and endocarditis suspected though cultures and PCR studies remained negative and a presumptive diagnosis of local dehiscence following infundibular muscle necrosis was made.

Late

There were 4 deaths overall; 2 of them died during follow-up (3 months to 1.5 years postoperatively) after a valve-sparing procedure, 1 from cardiac arrhythmia ($n=1$) and 1 from sepsis due to intravenous drug abuse ($n=1$). Survival was 85% at 10 and 15 years, respectively; freedom from cardiac death was 89% at 10 and 15 years, respectively.

Two patients died after valve replacement (cardiac cause $n=2$) and 2 after valve-sparing procedure (cardiac cause $n=1$). Survival

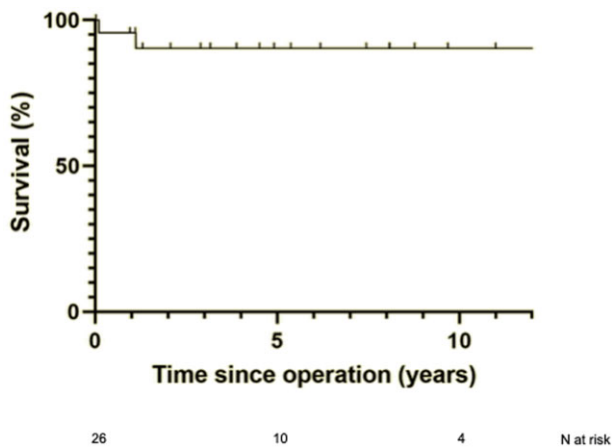


Figure 1: Freedom from cardiac death of patients after valve-sparing procedures as autograft reoperation.

was 90% at 10 and 15 years, respectively, after valve-sparing procedure and 50% at 10 and 15 years, respectively, after valve replacement. Freedom from cardiac death was 96% at 10 and 15 years, respectively, after valve-sparing procedure (Fig. 1) and 50% at 10 and 15 years, respectively, after valve replacement.

Reinterventions

Two patients (7%) underwent reinterventions on the autograft (at 2 and 16 years) after valve-sparing procedures. One patient developed recurrent AR after root remodelling with repair; cusp perforation was found at reoperation, most likely related to healed endocarditis. The patient received a mechanical valve replacement and has had no complications since. The second patient underwent re-reoperation after isolated cusp repair for autograft dilatation 16.4 years postoperatively. The patient underwent a valve-sparing procedure as her fourth operation. The patient has had no complications since.

Overall freedom from autograft reoperation was 95% at 10 and 15 years. Freedom from reoperation was 100% at 10 and 15 years after valve replacement and 94% at 10 and 15 years after valve-sparing procedure (Fig. 2).

Among the valve-sparing procedures, freedom from reoperation at 8 years was 100% after isolated cusp repair and 88% after root remodelling \pm cusp repair ($P=0.18$).

Autograft regurgitation

The valve remained competent in all patients who underwent isolated valve repair. Patients who underwent root remodelling and cusp repair developed AR \geq II in 3 cases. Freedom from AR \geq II was 83% at 8 years and was similar with the different repair procedures. It was 100% after isolated cusp repair ($n=7$) and root remodelling ($n=2$) versus 75% after combined root remodelling with cusp repair ($n=16$; $P=0.61$).

Three patients developed AR \geq II after root remodelling (concomitant cusp repair $n=2$, without cusp repair $n=1$) between 4 and 6 years postoperatively. It has remained stable as AR II in 2 patients, who developed AR II after 4 and 5 years, currently 8 and 9 years postoperatively. In one instance, AR progressed to AR grade III at 6 years after the reoperation. Clinical status,

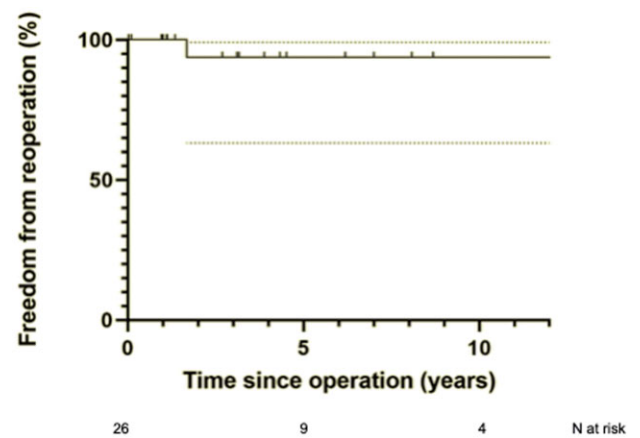


Figure 2: Freedom from autograft re-reoperation after valve-sparing procedures.

ventricular size and function, and grade of AR have remained stable since, currently 9 years postoperatively.

COMMENT

While the Ross procedure has been associated with excellent survival and freedom from valve-related complications, reoperations on the autograft will become necessary with a certain probability. Principally, 2 different mechanisms of autograft failure have been identified [8, 9, 12, 25, 26]. Autograft dilatation has been found more frequently following the root replacement technique [8, 12], while cusp prolapse—possibly resulting from distortion of commissural configuration—has been observed after subcoronary implantation [20, 25]. Finally, lesser degrees of autograft dilatation—i.e. involving the autograft sinotubular junction—may occur in combination with cusp distortion. Thus, the mechanisms of autograft dilatation appear similar to the different mechanisms of native aortic valve regurgitation.

The concept of valve preserving procedures for autograft failure appears principally attractive since it may preserve the advantages of the native valve. Pulmonary autograft valves rarely calcify and therefore represent an optimal substrate for repair [3]. In our cohort, degenerative cusp changes only occurred in 2 patients with systemic inflammatory disease. Autograft repair, however, has generally been chosen in a limited proportion of cases [12, 16, 20].

The reasons for the limited durability of autograft preservation in other series [12, 16] may be related to the different mechanisms of failure and regurgitation. The most frequent mechanism of failure after autograft root replacement is autograft dilatation with or without regurgitation [9, 12, 26]. In our experience, autograft root aneurysm, with variable degrees of regurgitation, was the most frequent finding and indication for reoperation. The mode of failure is also related to the technique of pulmonary autograft replacement. While the cylinder technique may offer a stabilizing effect, we have been concerned about possible negative effects of prosthetic material [7]. In our experience, a stabilizing technique using the remnants of the native aorta as part of the full-root technique appears to be a more straightforward approach. It also provides physiological haemodynamics. In a comparative study by our group [7], we saw a significantly better freedom from reoperation applying this technique as well as less

progression in root size per year. The vascular graft inclusion technique seems to allow for less physiological pulsatility and haemodynamics and long-term results are not yet available for this technique. In addition, a suture annuloplasty was added to the Ross procedure if the annulus was >26 mm. In our experience, the dilatation occurred at the sinus and sinotubular junction level rather than the annulus.

Autograft dilatation—if it occurs—can easily be diagnosed and quantified by standard imaging; it may be treated by valve-preserving root replacement, which is mostly done without cusp repair. Such an approach is appropriate if root dilatation is the only mechanism of failure. This is similar to native root aneurysm in which, in the absence of cusp pathology, valve preserving root replacement should normalize valve anatomy and function [24, 27]. In native aortic root aneurysm, however, we have found concomitant cusp prolapse in the vast majority of cases [14, 23, 27, 28]. It commonly becomes only evident after completion of root repair [28]. Furthermore, it is more frequently detected through intraoperative measurement of cusp configuration [23] rather than visual assessment, which is still the routine in many centres [13, 16, 17]. In our series, concomitant cusp prolapse was present in 13 out of 19 instances of autograft dilatation and became evident after completion of root replacement.

The second, more important reason for autograft failure is cusp-related [8, 28]. It becomes apparent earlier than autograft dilatation [8, 29, 30] and can be masked by the dilating process and cusp stretching [28–30]. It may be related to distortion of commissural position at the time of the Ross procedure. In our series, isolated cusp-related autograft failure with preserved root dimensions was less frequent. Isolated repair has been performed infrequently for valve repair [21]. In one series [16], 13 (out of 26) procedures were done as cusp repair. Interestingly, the majority of patients exhibited variable degrees of regurgitation at hospital discharge [16], and freedom from recurrent regurgitation after isolated repair was 50% at 3 years [16]. Two out of 4 patients treated by isolated valve repair required reoperation for recurrent regurgitation. The 2 non-reoperated patients presented with recurrent regurgitation grade \geq II at the last follow-up. By comparison, in our cohort, 8-year freedom from relevant regurgitation after isolated cusp repair was 100%. The precise reasons for this unexpectedly positive result of valve repair are difficult to determine. It may be related to our routine use of intraoperative measurement of effective height, which has been associated with better long-term results also in isolated tricuspid aortic valve repair [31].

It remains open whether valve reimplantation or root remodelling—as in this series—is the more appropriate form of valve-sparing procedure. In the hands of experienced surgeons, the durability of root remodelling and reimplantation are apparently similar in the native aorta [24, 27]. Most surgeons appear to prefer reimplantation to remodelling, also for the failed autograft. In the latter setting, this involves deep annular dissection, which may be technically difficult if foreign material has been implanted for annular stabilization during the Ross procedure. We have encountered scenarios in which the foreign material and scarring of the annular plane was so severe that the annulus was fixed in a dilated position. Placing this amount of tissue into a vascular graft may lead to functional stenosis. We thus prefer remodelling with lesser need for basal dissection; if an annuloplasty is necessary, it can easily be added in the form of a suture annuloplasty [22].

Valve-sparing procedures after pulmonary autograft replacement can be performed with a low perioperative morbidity [12, 16, 17, 21, 22]. In our cohort, no patients required a permanent pacemaker implantation or returned to the operating room for bleeding. There were no early deaths; however, 2 early deaths occurred after mechanical valve replacement. There were no early reoperations and only 2 patients required late reintervention after valve-sparing procedures for endocarditis and root dilatation. Patients who did not require a reintervention were in excellent clinical condition with good autograft valve function at last follow-up. Ultimately, our approach preserves the advantages that were intended for at the time of the initial Ross procedure.

Limitations

The main limitation of this study is its observational design. Although data of consecutive procedures were obtained prospectively, the analysis was performed retrospectively, and treatment allocation was not randomized. The reproducibility of our findings may be limited due to a highly experienced surgeon in a high-volume centre performing the procedures. Despite these limitations, this study is one of few long-term studies of the results of valve-sparing procedures after failure of pulmonary autograft replacement.

CONCLUSION

In conclusion, valve-sparing procedures after pulmonary autograft failure led to good long-term durability. This holds true for both root remodelling and isolated cusp repair if cusps are adequately assessed by measurement of effective and geometric height. Using such an approach, the autograft can be preserved, keeping alive the advantages initially intended for at the time of the Ross procedure.

Funding

None declared.

Conflict of interest: None of the authors have any conflicts of interest to declare.

DATA AVAILABILITY

The data underlying this article will be shared on reasonable request to the corresponding author.

Author contributions

Karen B. Abeln: Conceptualization; Data curation; Formal analysis; Visualization; Writing—original draft. **Tristan Ehrlich:** Data curation; Formal analysis. **Idriss Souko:** Investigation; Methodology. **Friederike Brenner:** Data curation. **Hans-Joachim Schäfers:** Conceptualization; Project administration; Supervision; Visualization; Writing—review & editing.

Reviewer information

Reviewer information European Journal of Cardio-Thoracic Surgery thanks Claudia Oeser, Gebrine El Khoury, Jan Vojacek and the other, anonymous reviewer(s) for their contribution to the peer review process of this article.

REFERENCES

- [1] El-Hamamsy I, Eryigit Z, Stevens L, Sarang Z, George R, Clark L *et al.* Long-term outcomes after autograft versus homograft aortic root replacement in adults with aortic valve disease: a randomised controlled trial. *Lancet* 2010;376:524–31.
- [2] Brown J, Ruzmetov M, Shahriari A, Rodefeld M, Mahomed Y, Turrentine M. Midterm results of Ross aortic valve replacement: a single-institution experience. *Ann Thorac Surg* 2009;88:601–7; discussion 607–8.
- [3] David T, Ouzounian M, David C, Lafreniere-Roula M, Manlihot C. Late results of the Ross procedure. *J Thorac Cardiovasc Surg* 2019;157:201–8.
- [4] Sievers H-H, Stierle U, Charitos E, Takkenberg J, Hörer J, Lange R *et al.* A multicentre evaluation of the autograft procedure for young patients undergoing aortic valve replacement: update on the German Ross Registry. *Eur J Cardiothorac Surg* 2016;49:212–8.
- [5] Mastrobuoni S, de Kerchove L, Solari S, Astarci P, Poncelet A, Noirhomme P *et al.* The Ross procedure in young adults: over 20 years of experience in our Institution. *Eur J Cardiothorac Surg* 2016;49:507–12; discussion 512–3.
- [6] Skillington P, Mokhles M, Takkenberg J, Larobina M, O'Keefe M, Wynne R *et al.* The Ross procedure using autologous support of the pulmonary autograft: techniques and late results. *J Thorac Cardiovasc Surg* 2015; 149:546–52.
- [7] Abeln K, Schäfers S, Ehrlich T, Federspiel J, Schäfers H-J. Ross operation with autologous external autograft stabilization—long-term results. *Ann Thorac Surg* 2022;114:502–9.
- [8] Mokhles M, Rizopoulos D, Andrinopoulou E, Bekkers J, Roos-Hesselink J, Lesaffre E *et al.* Autograft and pulmonary allograft performance in the second post-operative decade after the Ross procedure: insights from the Rotterdam Prospective Cohort Study. *Eur Heart J* 2012;33:2213–24.
- [9] Hokken R, Takkenberg J, van Herwerden L, Roelandt J, Bogers A. Excessive pulmonary autograft dilatation causes important aortic regurgitation. *Heart* 2003;89:933–4.
- [10] Leontyev S, Borger M, Davierwala P, Walther T, Lehmann S, Kempfert J *et al.* Redo aortic valve surgery: early and late outcomes. *Ann Thorac Surg* 2011;91:1120–6.
- [11] Stelzer P, Mejia J, Williams E. Outcomes of reoperations after Ross procedure. *Ann Cardiothorac Surg* 2021;10:491–8.
- [12] Bekkers J, Klieverik L, Raap G, Takkenberg J, Bogers A. Aortic root reoperations after pulmonary autograft implantation. *J Thorac Cardiovasc Surg* 2010;140:558–63; discussion S86–91.
- [13] Luciani G, Viscardi F, Pilati M, Prioli A, Faggian G, Mazzucco A. The Ross-Yacoub procedure for aneurysmal autograft roots: a strategy to preserve autologous pulmonary valves. *J Thorac Cardiovasc Surg* 2010;139: 536–42.
- [14] Sarsam M, Yacoub M. Remodeling of the aortic valve anulus. *J Thorac Cardiovasc Surg* 1993;105:435–8.
- [15] Langer F, Aicher D, Kissinger A, Wendler O, Lausberg H, Fries R *et al.* Aortic valve repair using a differentiated surgical strategy. *Circulation* 2004;110:1167–73.
- [16] de Kerchove L, Boodhwani M, Etienne P, Poncelet A, Glineur D, Noirhomme P *et al.* Preservation of the pulmonary autograft after failure of the Ross procedure. *Eur J Cardiothorac Surg* 2010;38:326–32.
- [17] Pettersson G, Subramanian S, Flynn M, Nowicki E, Batizy L, Svensson L *et al.* Reoperations after the Ross procedure in adults: towards autograft-sparing/Ross reversal. *J Heart Valve Dis* 2011;20:425–32.
- [18] Kumar S, Bansal N, Wells W, Starnes V. Outcomes of reintervention on the autograft after Ross procedure. *Ann Thorac Surg* 2016;102:1517–21.
- [19] Ratschiller T, Eva S, Schimetta W, Paulus P, Müller H, Zierer A *et al.* Valve-sparing root replacement for freestanding pulmonary autograft aneurysm after the Ross procedure. *J Thorac Cardiovasc Surg* 2018;155: 2390–7.
- [20] Charitos E, Takkenberg J, Hanke T, Gorski A, Botha C, Franke U *et al.* Reoperations on the pulmonary autograft and pulmonary homograft after the Ross procedure: an update on the German Dutch Ross Registry. *J Thorac Cardiovasc Surg* 2012;144:813–21; discussion 821–3.
- [21] Mookhoek A, de Kerchove L, Khoury E, Weimar G, Luciani T, Mazzucco GA *et al.* European multicenter experience with valve-sparing reoperations after the Ross procedure. *J Thorac Cardiovasc Surg* 2015;150: 1132–7.
- [22] Abeln K, Ehrlich T, Hess A, Schäfers H-J. Valve-sparing procedure for a dilated pulmonary autograft. *Ann Cardiothorac Surg* 2021;10:555–7.
- [23] Schäfers H-J, Bierbach B, Aicher D. A new approach to the assessment of aortic cusp geometry. *J Thorac Cardiovasc Surg* 2006;132:436–8.
- [24] Graeter T, Aicher D, Langer F, Wendler O, Schäfers H-J. Mid-term results of aortic valve preservation: remodelling vs. reimplantation. *Thorac Cardiovasc Surg* 2002;50:21–4.
- [25] Oswalt J, Dewan S, Mueller M, Nelson S. Highlights of a ten-year experience with the Ross procedure. *Ann Thorac Surg* 2001;71:5332–35.
- [26] Mazine A, El-Hamamsy I, Verma S, Peterson M, Bonow R, Yacoub M *et al.* Ross procedure in adults for cardiologists and cardiac surgeons: JACC state-of-the-art review. *J Am Coll Cardiol* 2018;72:2761–77.
- [27] Kuniyama T, Aicher D, Rodionychewa S, Groesdonk H, Langer F, Sata F *et al.* Preoperative aortic root geometry and postoperative cusp configuration primarily determine long-term outcome after valve-preserving aortic root repair. *J Thorac Cardiovasc Surg* 2012;143:1389–95.
- [28] Ehrlich T, Hagendorff A, Abeln K, Froede L, Giebels C, Schäfers H-J. Aortic cusp abnormalities in patient with trileaflet aortic valve and root aneurysm. *Heart* 2022;109:55–62.
- [29] David T, Omran A, Ivanov J, Armstrong S, de Sa M, Sonnenberg B *et al.* Dilation of the pulmonary autograft after the Ross procedure. *J Thorac Cardiovasc Surg* 2000;119:210–20.
- [30] Tamer S, Mastrobuoni S, van Dyck M, Navarra E, Bollen X, Poncelet A *et al.* Free margin length and geometric height in aortic root dilatation and leaflet prolapse: implications for aortic valve repair surgery. *Eur J Cardiothorac Surg* 2020;57:124–32.
- [31] Anand J, Schafstedde M, Giebels C, Schäfers H-J. Significance of effective height and mechanism of regurgitation in tricuspid aortic valve repair. *Ann Thorac Surg* 2023;115:429–35.