



# Characteristics and outcome of pediatric renal cell carcinoma patients registered in the International Society of Pediatric Oncology (SIOP) 93-01, 2001 and UK-IMPORT database: A report of the SIOP-Renal Tumor Study Group

Justine N. van der Beek<sup>1,2</sup>  | Janna A. Hol<sup>1</sup> | Aurore Coulomb-l'Hermine<sup>3</sup> | Norbert Graf<sup>4</sup> | Harm van Tinteren<sup>5</sup> | Kathy Pritchard-Jones<sup>6</sup> | Maite E. Houwing<sup>1</sup> | Ronald R. de Krijger<sup>1,7</sup> | Gordan M. Vujanic<sup>8</sup> | Kristina Dzhuma<sup>6</sup> | Jens-Peter Schenk<sup>9</sup> | Annemieke S. Littooi<sup>1,2</sup> | Gema L. Ramírez-Villar<sup>10</sup> | Dermot Murphy<sup>11</sup> | Satyajit Ray<sup>11</sup> | Reem Al-Saadi<sup>6,12</sup> | Manfred Gessler<sup>13</sup>  | Jan Godzinski<sup>14,15</sup> | Christian Ruebe<sup>16</sup> | Paola Collini<sup>17</sup> | Arnaud C. Verschuur<sup>18</sup> | Tony Frisk<sup>19</sup> | Christian Vokuhl<sup>20</sup> | Christina A. Hulsbergen-van de Kaa<sup>21</sup> | Beatriz de Camargo<sup>22</sup> | Bengt Sandstedt<sup>23</sup> | Barbara Selle<sup>24</sup> | Godelieve A. M. Tytgat<sup>1</sup> | Marry M. van den Heuvel-Eibrink<sup>1</sup>

<sup>1</sup>Princess Máxima Center for Pediatric Oncology, Utrecht, The Netherlands

<sup>2</sup>Department of Radiology and Nuclear Medicine, University Medical Center Utrecht/Wilhelmina Children's Hospital, Utrecht University, Utrecht, The Netherlands

<sup>3</sup>Sorbonne Université/Assistance Publique Hôpitaux de Paris-Hôpital Armand Trousseau, Paris, France

<sup>4</sup>Department of Pediatric Oncology and Hematology, Saarland University Medical Center and Saarland University Faculty of Medicine, Homburg, Germany

<sup>5</sup>Netherlands Cancer Institute, Amsterdam, The Netherlands

<sup>6</sup>UCL Great Ormond Street Institute of Child Health, University College London, London, UK

<sup>7</sup>Department of Pathology, University Medical Center Utrecht, Utrecht, The Netherlands

<sup>8</sup>Department of Pathology, Sidra Medicine, Doha, Qatar

<sup>9</sup>Clinic of Diagnostic and Interventional Radiology, Division of Pediatric Radiology, Heidelberg University Hospital, Heidelberg, Germany

<sup>10</sup>Department of Paediatric Oncology, Hospital Universitario Virgen del Rocío, Seville, Spain

<sup>11</sup>Department of Paediatric Oncology, Royal Hospital for Children, Glasgow, Scotland

<sup>12</sup>Department of Histopathology, Great Ormond Street Hospital for Children NHS Foundation Trust, London, UK

<sup>13</sup>Theodor-Boveri-Institute/Biocenter, University of Wuerzburg, Wuerzburg, Germany

<sup>14</sup>Department of Paediatric Surgery, Marciniak Hospital, Wroclaw, Poland

<sup>15</sup>Department of Paediatric Traumatology and Emergency Medicine, Marciniak Hospital, Wroclaw, Poland

<sup>16</sup>Department of Radiation Oncology, Saarland University Medical Center and Saarland University Faculty of Medicine, Homburg, Germany

<sup>17</sup>Department of Pathology, Fondazione IRCCS Istituto Nazionale dei Tumori, Milano, Italy

<sup>18</sup>Department of Pediatric Oncology, Hôpital d'Enfants de la Timone, Marseille, France

<sup>19</sup>Department of Women's and Children's Health, Karolinska Institutet, Stockholm, Sweden

**Abbreviations:** 5y, five-year; AJCC, American Joint Committee on Cancer; EFS, event-free survival; MiT, microphthalmia transcription factor; MiT-RCC, translocation type renal cell carcinoma; NSS, nephron-sparing surgery; OS, overall survival; RCC, renal cell carcinoma; RTSG, Renal Tumor Study Group; SIOP, International Society of Pediatric Oncology; TFE3, transcription factor E3; TFE3, transcription factor EB; WHO, World Health Organization.

This is an open access article under the terms of the Creative Commons Attribution-NonCommercial-NoDerivs License, which permits use and distribution in any medium, provided the original work is properly cited, the use is non-commercial and no modifications or adaptations are made.

© 2021 The Authors. *International Journal of Cancer* published by John Wiley & Sons Ltd on behalf of UICC.

<sup>20</sup>Section of Pediatric Pathology, University Hospital Bonn, Bonn, Germany

<sup>21</sup>Laboratory of Pathology East Netherlands (LABPON), Hengelo, The Netherlands

<sup>22</sup>Research Program, Instituto Nacional de Cancer, Rio de Janeiro, Brazil

<sup>23</sup>Childhood Cancer Research Unit, Astrid Lindgren's Children's Hospital, Karolinska Institutet, Stockholm, Sweden

<sup>24</sup>Department of Pediatric Hematology and Oncology, St. Annastift Children's Hospital, Ludwigshafen, Germany

### Correspondence

Justine N. van der Beek, Department of Radiology and Nuclear Medicine, University Medical Center Utrecht/Wilhelmina's Children's Hospital, Heidelberglaan 100, 3584 CX Utrecht, The Netherlands. Email: j.n.vanderbeek-6@umcutrecht.nl

### Funding information

Children's Cancer and Leukaemia Group/Little Princess Trust, Grant/Award Number: CCLGA 2019 27B; Children's Cancer and Leukaemia Group/Bethany's Wish, Grant/Award Number: CCLGA 2017 02; Great Ormond Street Hospital Children's Charity, Grant/Award Number: W1090; Stichting Kinderen Kankervrij, Grant/Award Number: 341

### Abstract

In children, renal cell carcinoma (RCC) is rare. This study is the first report of pediatric patients with RCC registered by the International Society of Pediatric Oncology-Renal Tumor Study Group (SIOP-RTSG). Pediatric patients with histologically confirmed RCC, registered in SIOP 93-01, 2001 and UK-IMPORT databases, were included. Event-free survival (EFS) and overall survival (OS) were analyzed using the Kaplan-Meier method. Between 1993 and 2019, 122 pediatric patients with RCC were registered. Available detailed data (n = 111) revealed 56 localized, 30 regionally advanced, 25 metastatic and no bilateral cases. Histological classification according to World Health Organization 2004, including immunohistochemical and molecular testing for transcription factor E3 (TFE3) and/or EB (TFEB) translocation, was available for 65/122 patients. In this group, the most common histological subtypes were translocation type RCC (MiT-RCC) (36/64, 56.3%), papillary type (19/64, 29.7%) and clear cell type (4/64, 6.3%). One histological subtype was not reported. In the remaining 57 patients, translocation testing could not be performed, or TFE-cytogenetics and/or immunohistochemistry results were missing. In this group, the most common RCC histological subtypes were papillary type (21/47, 44.7%) and clear cell type (11/47, 23.4%). Ten histological subtypes were not reported. Estimated 5-year (5y) EFS and 5y OS of the total group was 70.5% (95% CI = 61.7%-80.6%) and 84.5% (95% CI = 77.5%-92.2%), respectively. Estimated 5y OS for localized, regionally advanced, and metastatic disease was 96.8%, 92.3%, and 45.6%, respectively. In conclusion, the registered pediatric patients with RCC showed a reasonable outcome. Survival was substantially lower for patients with metastatic disease. This descriptive study stresses the importance of full, prospective registration including TFE-testing.

### KEYWORDS

pediatric, renal cell carcinoma, survival, treatment

## 1 | INTRODUCTION

While renal cell carcinoma (RCC) is the most common renal tumor in adults, it accounts for 2% to 6% of malignant renal tumors in the pediatric population.<sup>1-4</sup> Our understanding of pediatric RCC has increased the past years; however, it still often remains based on knowledge of adult RCC.<sup>3,5</sup> From the few studies that have described pediatric RCC cohorts, it has become clear that compared to RCC in adult patients, childhood RCC has distinct clinical, histological and molecular characteristics.<sup>3,6-8</sup> In adults, clear cell RCC represents the predominant histological subtype, whereas in children distribution of subtypes is different.<sup>5,9,10</sup> Translocation-type RCC (MiT-RCC), officially recognized by the World Health Organization (WHO) in 2004, is characterized by translocations including transcription factor E3 (TFE3) or

### What's new?

Pediatric renal cell carcinoma (RCC) is a rare malignancy, knowledge of which is based largely on adult RCC. Here, pediatric RCC was retrospectively studied using data from the International Society of Pediatric Oncology – Renal Tumor Study Group (SIOP-RTSG). Pediatric RCC patients had a 5-year overall survival rate of 84.5 percent, with notably lower survival for patients with metastatic disease. In pediatric RCC patients tested for transcription factor E3 and EB, 56.3 percent presented with translocation type. The findings highlight the importance of full registration of pediatric RCCs, with information on germline genetics and transcription factor testing.

transcription factor EB (TFEB), which are members of the microphthalmia transcription factor (MiT) family. In children, this is the most prevalent RCC type.<sup>3</sup> The most frequent translocation affects the *TFE3 gene*, located on Xp11.2.<sup>5</sup> The diagnosis of MiT-RCC can be confirmed by cytogenetic analyses and/or immunohistological staining for TFE3 or TFEB. Before the use of the WHO 2004 classification system, pediatric RCCs most commonly described had been clear cell and papillary RCC types, both showing a considerable morphological overlap with the currently acknowledged MiT-RCC.<sup>10,11</sup>

Reported 5-year (5y) survival rates for pediatric RCC vary between 60% and 85%.<sup>6,9,12</sup> The most effective treatment of localized pediatric RCC consists of radical tumor nephrectomy without adjuvant therapy.<sup>2</sup> Nephron-sparing surgery (NSS) has been described as an effective treatment option for selected cases in small pediatric cohorts.<sup>6,13</sup> Even despite current, novel adjuvant therapy options, survival rates for metastatic pediatric RCC have been described to be lower than 15%.<sup>6,12,14</sup>

Most of the previously published studies describing pediatric RCC are from the United States, Canada and national reports from European countries.<sup>3,9,10,15</sup> So far, the International Society of Pediatric Oncology (SIOP)-Renal Tumor Study Group (RTSG) has never reported the RCC cases registered in their database. Here, we describe the first series of pediatric patients with RCC, prospectively registered in the SIOP 93-01, 2001 and UK-IMPORT database. This descriptive study focusses on patient characteristics and survival of children in pediatric RCC.

## 2 | PATIENTS AND METHODS

### 2.1 | Patient and data collection

All pediatric patients (0-18 years), diagnosed with histologically proven RCC and registered in the SIOP (93-01 [1993-2001], 2001 [2001-2018] and UK-IMPORT [2012-2019]) databases, were included. These clinical trials and studies were primarily focused on Wilms' tumor patients but allowed prospective registration of pediatric RCC cases and collection of observational clinical, pathological and outcome data. Details on presenting symptoms were not available, and are therefore not included in this report. Informed consent from registration in the SIOP 93-01, SIOP 2001 and UK-IMPORT studies had been obtained from parents of included pediatric patients prior to treatment, according to national law and regulations.

### 2.2 | Histopathology

The SIOP-RTSG panel of pathologists centrally reviewed most included cases within the SIOP 93-01, 2001 and UK-IMPORT protocols. Histology was, where feasible, classified according to the 2004 "WHO Classification of Tumours of the Urinary system and Male Genital Organs."<sup>8,16</sup> All effort was put into retrieving missing histopathological information and/or slides to perform TFE-FISH and/or TFE-immunohistochemistry, and review materials in retrospect in case of missing information.

Ultimately, for cases without available TFE-translocation testing and without available stored materials for TFE-FISH or TFE-immunohistochemistry, previous classifications were used.<sup>17</sup>

### 2.3 | Staging

The most commonly used staging system for RCC is the American Joint Committee on Cancer (AJCC) TNM staging system.<sup>18</sup> In the SIOP database, patients had been registered according to the SIOP Staging Criteria.<sup>19</sup> Therefore, we reclassified the stage for all patients identified in the SIOP 93-01, 2001 and UK-IMPORT databases and used the 7th Edition AJCC TNM classification (group I-V) based on primary tumor (T), nodal status (N) and presence of metastatic disease (M). Since tumor size was reported in volume rather than in tumor diameter, it was impossible to distinguish T1 from T2 tumors. Furthermore, relation to Gerota's fascia is not included in the SIOP Staging Criteria, whereas tumor rupture and completeness of tumor resection is not specifically included in the TNM staging system. Therefore, differentiation of T3 and T4 tumors was complicated. Since in recent literature in RCC tumor invasion beyond Gerota's fascia seems to be very rare, if not mostly absent, tumors with SIOP stage II or III were classified as T3 in case of doubt (Table S1A).<sup>5,9</sup> For the current descriptive study, in order to use the most representative staging system possible, a combined tumor stage was used to classify disease as localized (T1/T2, N0, M0), regionally advanced (T3, any N, M0 or any T, N1, M0) or metastatic (any T or N and M1) (Tables 1 and S1B).<sup>20</sup> Tumor volume at diagnosis and at surgery was calculated using the following formula: 0.523 times the product of the three tumor dimensions, if available. Since radiological data was not systematically captured, tumor response was, where possible, determined using an arbitrarily decided 10% increase or decrease of tumor volume as cutoff value, derived from the RECIST-criteria.

### 2.4 | Treatment

The SIOP 93-01 and SIOP 2001 protocols recommended use of preoperative chemotherapy for patients >6 months of age, without histological assessment for most children presenting with a renal tumor. Only for patients aged 6 years or older, and/or in cases with unusual clinical presentations, such as a urinary infection, and/or unusual findings upon imaging, such as tumor calcification or no visible renal parenchyma, a biopsy to obtain histological diagnosis was recommended. In UK-IMPORT and UK SIOP 2001, a biopsy for histological assessment before preoperative chemotherapy was done in virtually all cases until 2019. Hence, younger patients were often treated with preoperative chemotherapy including vincristine and actinomycin-D for a period of 4 weeks for localized disease, or in case of metastatic disease, for a period of 6 weeks with the addition of epirubicin or doxorubicin, prior to nephrectomy. The SIOP protocols 93-01, 2001 and UK-IMPORT did not provide standardized treatment recommendation for pediatric RCC but, for the patients described in

**TABLE 1** Patient and disease characteristics (n = 122)

		n	Percentage	
SIOP-protocol	93-01	39	32.0	
	2001	73	59.8	
	UK-IMPORT	10	8.2	
Gender	Male	62	50.8	
	Female	60	49.2	
Age at diagnosis	0-5 years	22	16.4	
	6-10 years	38	31.1	
	11-18 years	64	52.5	
Tumor side	Left	60	49.2	
	Right	62	50.8	
Lymph node status <sup>a</sup>	Positive	38	37.3	
	Negative	64	62.7	
	Missing	20	—	
Stage	Localized	56	50.5	
	Regionally advanced <sup>a</sup>	30	27.0	
	Metastatic <sup>b</sup>	25	22.5	
	Missing	11	—	
Histology	Not TFE-tested/testing unknown (n = 57)	Papillary type 1/2	21	44.7
		Clear cell	11	23.4
		Combination clear cell and papillary type	2	4.3
		Renal medullary carcinoma	3	6.4
		Collecting duct carcinoma	1	2.1
		Unclassified	9	19.1
		Missing	10	—
	TFE-tested (n = 65)	MiT-family translocation type	36	56.3
		Papillary type 1/2	19	29.7
		Clear cell	4	6.3
		Chromophobe RCC	2	3.1
		Succinate dehydrogenase deficient RCC	2	3.1
		Unclassified	1	1.6
		Missing	1	—

Abbreviations: MiT, microphthalmia transcription factor; RCC, renal cell carcinoma.

<sup>a</sup>Lymph node status was positive in case of regionally advanced disease (N1).

<sup>b</sup>Metastatic stage included positive lymph nodes classified as distant metastases (M1).

this cohort, surgery was considered the mainstay of therapy for nonmetastatic RCC.

## 2.5 | Outcome analysis

Event-free survival (EFS) and overall survival (OS) were estimated using the Kaplan-Meier method. EFS was defined as time from diagnosis to the first relapse, or death for any reason. Patients were censored at the time of the last follow-up record. Outcome results are reported for the whole RCC cohort, as well as separately for the group of patients tested for MiT-RCC. Analysis was performed using SPSS, version 20.0.

## 3 | RESULTS

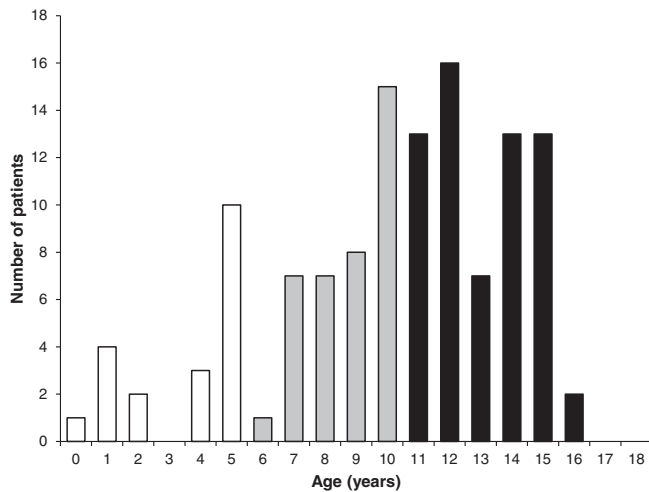
### 3.1 | Patient characteristics

In total, 6492 patients with a renal tumor were registered (SIOP 93-01 n = 1104, SIOP 2001 n = 4696, UK-IMPORT n = 692). In this cohort, 122 patients (1.9%) were diagnosed with pediatric RCC (SIOP 93-01 n = 39, SIOP 2001 n = 73, UK-IMPORT n = 10) (Tables 1 and S3A,B). Twelve patients have already been reported in the previously published study by Selle et al.<sup>9</sup> Sixty-two out of 122 (50.8%) patients were male. Median age at diagnosis was 11.3 years (range 0.8-16.6 years). Approximately half of the

patients were diagnosed in the first decade of life (47.5%) (Figure 1, Table 1).

### 3.2 | Tumor characteristics

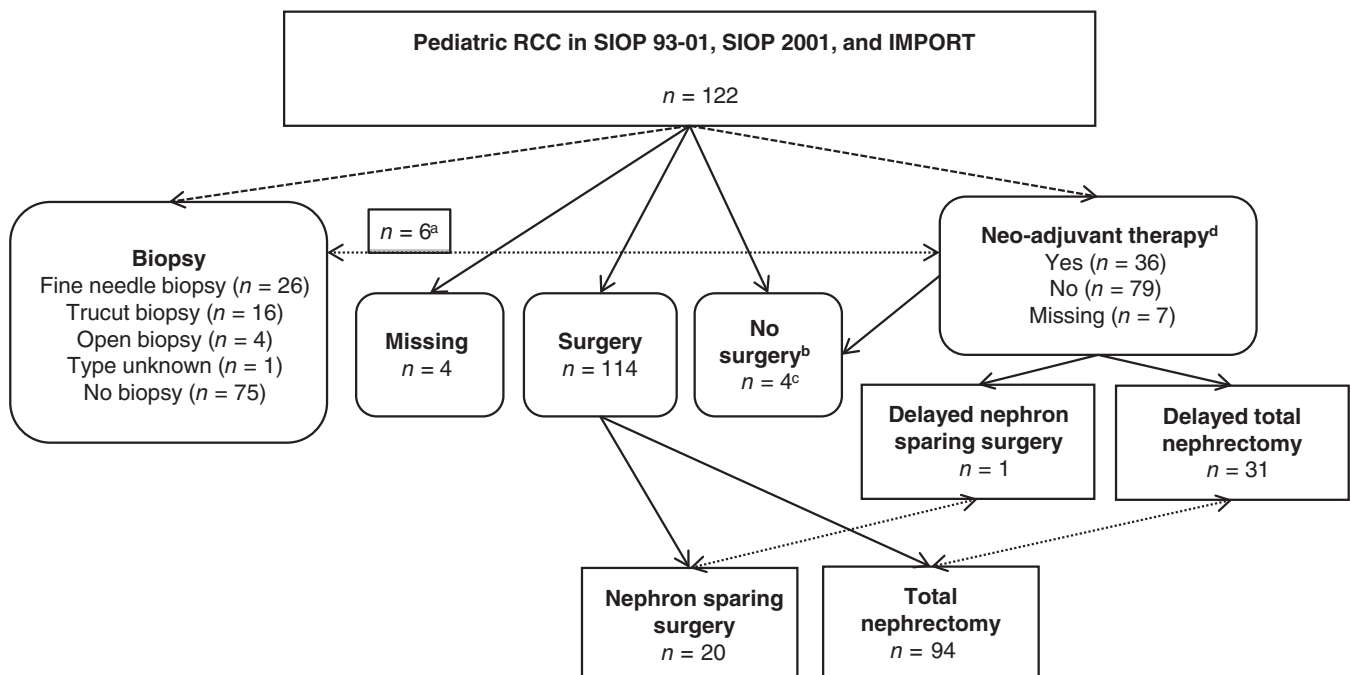
Tumor stage was recorded for 111 patients: 56/111 (50.5%) had localized (T1/T2, N0, M0), 30/111 (27.0%) regionally advanced (T3,



**FIGURE 1** Distribution of age at diagnosis in years. Age distributed in age groups, in concordance with Table 1: ○ 0 to 5 years; ● 6 to 10 years; ● 11 to 18 years

any N, M0 or any T, N1, M0) and 25/111 (22.5%) metastatic disease (any T or N and M1) (Tables 1 and S1B). Sixty tumors (49.2%) were left-sided and 62 tumors (50.8%) were right-sided. No bilateral RCCs were registered. Details on regional lymph node status (N0 or N1) were available from 102 patients (Table 1). Positive lymph nodes were detected in 38/102 (37.3%) patients, resulting in N1 following the TNM classification system. When lymph nodes were considered as the site of distant metastasis (M1), this was described as such in the database. These patients were classified as having “metastatic disease.” Rupture of the tumor capsule had occurred in 11/102 (10.8%) patients, of which four ruptures occurred preoperatively and four during surgery. The moment of rupturing was not reported for the remaining three cases. Median tumor volume at diagnosis was 78.5 mL (range 0.5-1019.5 mL). The median tumor volume according to stage, reported in 103 patients, was 69.0 mL (range 1.1-1019.5 mL) for localized, 33.5 mL (range 0.5-878.6 mL) for regionally advanced and 220.0 mL (30.0-790.8 mL) for metastatic disease. Median age was equally distributed between the different disease stages, with a median age of 11.5 years (range 0.8-16.6 years) for localized, 10.1 years (range 2.4-16.6 years) for regionally advanced and 11.5 years (range 1.2-15.3 years) for metastatic disease.

Twenty-five patients presented with metastatic disease at diagnosis. The sites of metastases were: lungs ( $n = 12$ ), abdomen (location unspecified) ( $n = 9$ ), lymph nodes ( $n = 7$ ), bone ( $n = 3$ ) and liver ( $n = 3$ ). In addition, nine patients were reported with metastases in more than one location. Forty-seven patients underwent a biopsy prior to surgery, in 26/47 (55.3%) patients this was a fine needle biopsy.



**FIGURE 2** Overview of treatment of pediatric patients with RCC registered in the SIOP 93-01, 2001 and UK-IMPORT databases. <sup>a</sup> Patients underwent a biopsy before or during neoadjuvant therapy; <sup>b</sup> No surgery was performed due to advanced metastatic disease; <sup>c</sup> Patients were only treated with neoadjuvant therapy; <sup>d</sup> Neoadjuvant therapy consisted of chemotherapy, targeted therapy and radiotherapy. RCC, renal cell carcinoma

The biopsied patients had a median age of 11.3 years ( $n = 47$ , range 0.8-16.6 years) (Figure 2).

### 3.3 | Histology

In 57/122 (46.7%) patients, TFE-assessment was not performed due to lack of upfront testing and/or unavailability of remaining slides/tumor samples. In this group, in 10/57 patients histological subtype was not reported. Twenty-one out of 47 (44.7%) tumors were classified as papillary type RCC, 11/47 (23.4%) tumors as clear cell RCC and 15/47 (31.9%) tumors as other RCC subtypes (Table 1).

In 65/122 (53.3%) patients MiT-RCC status was assessed, predominantly by TFE3-immunohistochemistry. In this group, in 1/65 patients histological subtype was not reported. MiT-RCC was confirmed in 36 of the 64 cases (56.3%), 19/65 (29.7%) of the cases were classified as papillary RCC, 4/64 (6.3%) of the cases as clear cell RCC and 5/64 (7.8%) were classified as other RCC subtypes (Table 1). The median age and median tumor volume in MiT-RCC confirmed patients was 10.3 years (range 1.2-16.6 years) and 47.5 mL (range 3.1-807.7 mL), respectively, whereas the median age was 12.3 years (range 0.8-15.4 years) and median tumor volume was 78.5 mL (range 7.7-1019.5 mL), in the patients without MiT-RCC, respectively.

### 3.4 | Initial treatment approach

Thirty-two patients had been treated with preoperative chemotherapy (Figure 2, Table S2). Specification of preoperative chemotherapy was available for 30 patients and had consisted of actinomycin-D and vincristine, in three cases in combination with epirubicin or doxorubicin. Response to preoperative chemotherapy was available for 23 patients, resulting in 11 patients with an evident decrease ( $\geq 10\%$ , range 10%-96%) of tumor volume ( $n = 11$  treated with actinomycin-D and vincristine only). Seven patients showed an evident increase ( $\geq 10\%$ , range 10%-1102%) of tumor volume ( $n = 5$  treated with actinomycin-D and vincristine only,  $n = 1$  treated with actinomycin-D,

vincristine and epirubicin and  $n = 1$  treated with actinomycin-D, vincristine and doxorubicin). The remaining five patients showed stable ( $< 10\%$ , range 0%-6%) disease ( $n = 4$  treated with actinomycin-D and vincristine, and  $n = 1$  treated with actinomycin-D, vincristine and epirubicin).

Four patients with metastatic disease had only been treated with neo-adjuvant therapy and did not undergo surgery. Their treatment consisted of a variety of combinations of targeted therapy and chemotherapy (Figure 2, Table S3A,B). For these patients, data regarding effect on tumor volume were lacking.

### 3.5 | Surgical approach

Surgical details were available for 114 patients. Ninety-four patients underwent a total nephrectomy and 20 patients underwent NSS (Figure 2). Patients who underwent NSS had smaller tumor volumes (median 38.6 mL [range 1.1-611.9 mL]), compared to tumors that underwent a total nephrectomy (median 89.4 mL [range 0.5-1019.5]). Of these 20 patients, nine had localized, three regionally advanced and three metastatic disease at diagnosis. For five patients, disease stage was unknown. Data on lymph node dissection were not available.

### 3.6 | Postoperative treatment

Disease stage and postoperative treatment were available of only 96 patients (Table 2). Forty-one out of 46 patients with localized disease received no adjuvant treatment, three received postoperative chemotherapy (predominantly actinomycin-D, vincristine and etoposide), and two patients received radiotherapy. Among the 26 patients with regionally advanced disease, five were treated with various combinations of postoperative chemotherapy (predominantly carboplatin, etoposide, ifosfamide, doxorubicin and vinblastine), six underwent radiotherapy and three patients had received immunotherapy with interleukin-2 and/or interferon- $\alpha$  (Table 2).

**TABLE 2** Postoperative treatment in pediatric patients with RCC shown per disease stage ( $n = 96$ )

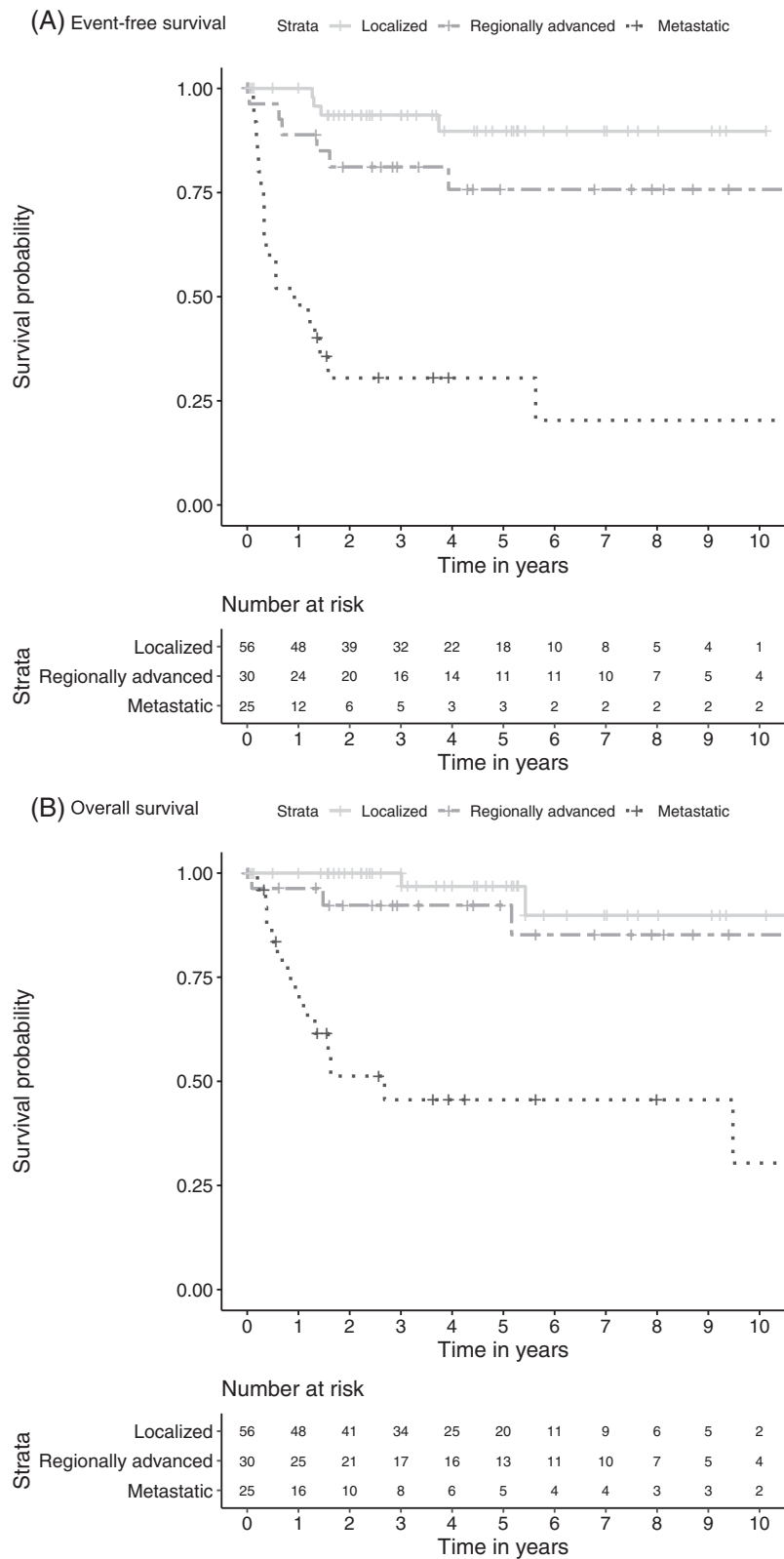
Postoperative treatment	Localized ( $n = 46$ ) T1/2-N0-M0	Regionally advanced ( $n = 26$ ) T3-N0/1-M0 Any T-N1-M0	Metastatic ( $n = 24$ ) Any T-Any N-M1	( $n = 96$ ) Total
None	41	18	12	71
Chemotherapy <sup>a</sup>	3	5	7	15
Immunotherapy <sup>b</sup>	0	3	3	6
Targeted therapy <sup>c</sup>	1	1	3	5
Radiotherapy	2	6	3	11

Abbreviation: RCC, renal cell carcinoma.

<sup>a</sup>Various combinations, consisting of vincristine, etoposide, carboplatin, ifosfamide, doxorubicin, vinblastine, cyclophosphamide, cisplatin, gemcitabine, adriamycin, actinomycin-D, epirubicin and paclitaxel.

<sup>b</sup>Consisting of monotherapy or a combination of interleukin-2 and interferon- $\alpha$ .

<sup>c</sup>New agents, consisting of axitinib, sorafenib, nivolumab, sunitinib and bortezomib.

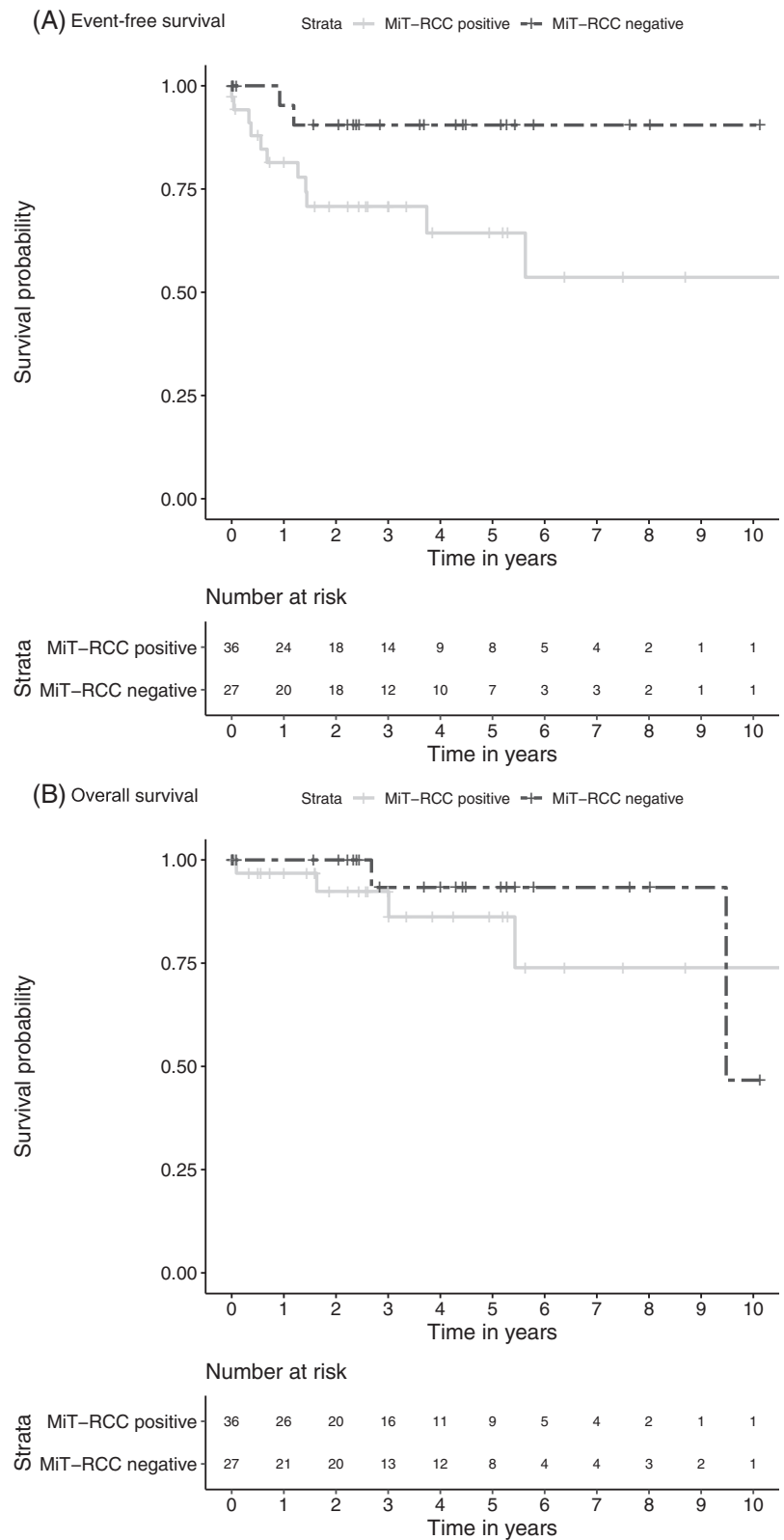


**FIGURE 3** Estimated, A, event-free survival and, B, overall survival for pediatric RCC patients according to disease stage. RCC, renal cell carcinoma

Seven out of 24 patients with metastatic disease received various combinations of adjuvant chemotherapy (predominantly etoposide, doxorubicin, cyclophosphamide, cisplatin, vinblastine, gemcitabine, capecitabine, vincristine, actinomycin-D, carboplatin, ifosfamide and paclitaxel). Immunotherapy had been administered in three patients,

and three patients underwent radiotherapy. This study did not focus on relapse patterns. However, with the growing interest in targeted therapy, we report on the data that were captured in the database. In five cases, targeted therapy agents (axitinib, sorafenib, nivolumab, sunitinib and/or bortezomib) had been administered (Table 2). Two patients, one

**FIGURE 4** Estimated, A, event-free survival and, B, overall survival in the TFE-tested group of MiT-RCC positive and MiT-RCC negative pediatric RCC patients. MiT-RCC, translocation type renal cell carcinoma; RCC, renal cell carcinoma



with localized and one with regionally advanced disease, had a relapse after a total nephrectomy, whereas one patient with metastatic disease relapsed after preoperative chemotherapy and a total nephrectomy. In the remaining two patients with metastatic disease, one relapsed, but data on preoperative therapy and surgery were missing.

### 3.7 | Outcome

Estimated 5y EFS and 5y OS of the total group (n = 122) was 70.5% (95% CI = 61.7%-80.6%) and 84.5% (95% CI = 77.5%-92.2%), respectively, after median follow-up of 3.9 years (95% CI = 3.0-5.1 years).



Twenty-nine out of 122 (23.8%) patients suffered a relapse, within a median time of 8.1 months (range 1-67.6 months). Eighteen out of these 29 relapsed patients had metastatic disease at diagnosis. Seventeen out of these 29 relapsed patients died within a median time of 1.3 years (range 1.2 months to 9.5 years).

Two out of 11 patients (18.2%) with a capsule rupture undergoing a total nephrectomy, one with regionally advanced disease at diagnosis and a major rupture during surgery and one with metastatic disease at diagnosis without further information available, relapsed and died after treatment. They had been treated with interleukin-2 and/or interferon- $\alpha$  after relapse, followed by gemcitabine and irinotecan in the regionally advanced case. Of the 20 patients that underwent NSS, four patients relapsed, of which three patients had metastatic disease at diagnosis, and for one patient disease stage was unknown. Two of these patients died, of which one after treatment with cisplatin, gemcitabine and paclitaxel.

Survival according to disease stage showed an estimated 5y EFS (n = 111) of 89.7% (95% CI = 80.2%-100%) for localized disease, 75.8% (95% CI = 60.3%-95.2%) for regionally advanced disease and 30.5% (95% CI = 16.5%-56.2%) for metastatic disease (Figure 3A). Patients with localized disease had an estimated 5y OS (n = 111) of 96.8% (95% CI = 90.8%-100%), with regionally advanced disease 92.3% (95% CI = 82.6%-100%), and patients with metastatic disease 45.6% (95% CI = 28.5%-72.9%) (Figure 3B). Of the 11/122 patients without available disease stage, 7/11 belonged to the TFE-tested group, whereas 4/11 lacked available TFE-test results.

Focusing on the TFE-tested group with adequate outcome data, the estimated 5y EFS of MiT-RCC patients (n = 36) was 64.3% (95% CI = 47.9%-86.5%). The MiT-RCC-negative patients (n = 27) showed a 5y EFS of 90.5% (95% CI = 78.8%-100%) (Figure 4A). The estimated 5y OS of the MiT-RCC patients (n = 36) was 86.2% (95% CI = 72.4%-100%) and of the MiT-RCC-negative patients (n = 27) was 93.3% (95% CI = 81.5%-100%) (Figure 4B). In the TFE-tested group, 7/9 (77.8%) metastatic cases, 11/14 (78.6%) regionally advanced cases and 13/34 (38.2%) localized cases were TFE-positive.

Patients with N1M0 (n = 21) had an estimated 5y EFS and 5y OS of 72.8% (95% CI = 52.2%-93.4%) and 89.7% (95% CI = 76.2%-100%), respectively, whereas patients with NOMO (n = 54) had an estimated 5y EFS and 5y OS of 86.8% (95% CI = 75.4%-98.2%) and 96.6% (95% CI = 90.0%-100%), respectively (Figure S1A,B).

## 4 | DISCUSSION

Pediatric RCC is a very rare tumor, and only a few reports are available that describe patient characteristics and survival in cohorts with substantial numbers.<sup>3,5,6</sup> The current retrospective descriptive study is the first report of the SIOP-RTSG describing the clinical characteristics and outcome of patients with pediatric RCC under the age of 19 years.

Due to the fact that the SIOP 93-01, 2001 and UK-IMPORT databases were designed to register mainly Wilms' tumor patients, pediatric RCC was likely underreported and registration was potentially

biased. Nevertheless, in accordance with previously published results, our series does not show gender predisposition, and an age distribution (median age of 11.3 years) consistent with a survey conducted by the Japanese Society of Pediatric Surgeons showing that 52.6% of the pediatric RCC patients is aged 10 to 15 years.<sup>3,21-23</sup> Geller et al reported a median age of 12.9 years (range 1.9-22.1 years) in a cohort of 120 pediatric and adolescent RCC patients.<sup>5</sup> Pediatric RCC has been shown to present with classic symptoms such as hematuria, abdominal/flank pain and/or palpable mass.<sup>15,24</sup> Since details on presenting symptoms were not captured in our databases, and details in medical records were incomplete, we could not show the presenting symptoms of the included patients. Furthermore, data on potential associated syndromes or association with Wilms' tumors had not been systematically collected in previous SIOP-databases. Future registries including SIOP-RTSG UMBRELLA 2016 will include registration of underlying syndromes such as von-Hippel-Lindau, Birt-Hogg-Dubé syndrome and tuberous sclerosis complex in pediatric RCC, since a variety of genes and syndromes are associated with an increased risk of this renal tumor.<sup>9,25-27</sup>

About 50% of the pediatric RCC patients presented with stage I-II disease, concordant with other available pediatric RCC registries.<sup>6,13,22</sup> We found 22.5% metastatic cases, consistent with the percentages of stage IV disease in the previous reports.<sup>3,5,9,12</sup> With the knowledge about pediatric RCC increasing over the past decades, no clear observable trend toward less advanced cases was observed over time, in accordance with RCC studies in children and young adolescents published from 1970 until 2018.<sup>28</sup>

Based on the epidemiological suspicion of a Wilms' tumor in the majority of children  $\leq$  10 years with renal tumors, many pediatric RCC cases had been pretreated with chemotherapy according to the SIOP-protocols. We observed a decrease of  $\geq$ 10% in tumor volume in 11/23 of the patients treated with preoperative chemotherapy and with available response data. However, administration of and response to preoperative chemotherapy was not captured systematically in the database for all patients, hence no firm conclusions can be drawn. Discrimination of RCC from Wilms' and other non-Wilms' tumors at initial presentation with the use of innovative radiology and other research strategies will be of great value for the future.<sup>29,30</sup> For instance, the direct correlation of diffusion weighted imaging and associated apparent diffusion coefficients combined with other imaging characteristics are anticipated to be of added value in the differentiation between different types of renal tumors and are therefore prospectively integrated in the current SIOP-RTSG UMBRELLA 2016 protocol.<sup>31,32</sup>

In our series, 94 patients underwent a total nephrectomy, and 20 patients underwent NSS. Even though there are a number of studies describing NSS for selected cases, the use of a less radical surgical approach is generally reserved for selected cases with a low stage tumor and potentially in cases of syndrome-associated RCC with a risk of metachronous and recurrent RCC, but only whenever obtaining negative margins seems feasible.<sup>5,13,33</sup> Furthermore, the implications of extensive lymph node dissection and second look surgery for additional lymph node sampling are still being debated.<sup>2,5,34</sup> Future studies

should focus on the role of lymph node dissection in the treatment of pediatric RCC.<sup>35,36</sup>

Adjuvant therapy strategies consisted of (combinations of) radiotherapy, chemotherapy, immunotherapy and/or targeted therapy. In this study, it was not systematically captured whether adjuvant therapy strategies in relapsed patients were administered postoperatively prior to relapse, as a treatment for relapse, or a combination of these situations. Furthermore, evidence for adjuvant therapy in stage III pediatric RCC is lacking, and the treatment approach in regionally advanced disease remains debatable.<sup>22,37</sup> In our cohort, 14 patients with regionally advanced disease received combined chemotherapy, radiotherapy and/or immunotherapy. Targeted therapy was registered for only one patient with regionally advanced disease. Based on lack of evidence for benefit in the SIOP-RTSG UMBRELLA study, it was therefore decided not to recommend any adjuvant therapy in stage III pediatric RCC.<sup>10,37,38</sup>

The SIOP 93-01, 2001 and UK-IMPORT protocols did not provide a standardized treatment recommendation for metastatic RCC. In our RCC-cohort, patients with metastatic disease received a variety of treatment strategies, predominantly consisting of postoperative chemotherapy. Targeted agents were administered in only three patients with metastatic disease. The UMBRELLA 2016 protocol recommends the use of sunitinib in metastatic pediatric RCC as the first-line adjuvant drug, since it improved progression-free survival in adult metastatic clear cell RCC and in adult and pediatric metastatic MiT-RCC.<sup>39-41</sup> Nevertheless, there is a lack of evidence for treatment of other histological subtypes of RCC in children and the potential beneficial effect of combining sunitinib with other agents.<sup>41</sup> Future studies may focus on the value of *novel* targeted agents.<sup>42</sup> A recent report showed that axitinib (a vascular endothelial growth factor inhibitor) might have a potentially beneficial effect in refractory pediatric solid tumors.<sup>43</sup> Furthermore, there are recent results showing an increased progression-free survival in advanced adult RCC when combining axitinib with avelumab, or with pembrolizumab.<sup>44,45</sup> Recently, in advanced adult RCC the multiple kinase inhibitor cabozantinib and several combinations of immune check point inhibitors showed an increased progression-free survival.<sup>46</sup>

Translocation type RCC (MiT-RCC) was formally recognized by the WHO in 2004 as a separate histological subtype with characteristic morphology, and by TFE3- and TFEB-related translocations.<sup>16</sup> Since then, in published series a shift in histological diagnoses was observed, which is also reflected in this current SIOP-RTSG registered cohort when comparing the patients assessed according to the WHO 2004 classification to patients assessed following previous classifications. Central review by the SIOP-RTSG pathology panel for UMBRELLA 2016 is currently performed following the most recent "2016 WHO Classification of Tumours of the Urinary system and Male Genital Organs."<sup>47</sup> For this cohort, it was impossible to reclassify the histological subtypes using the most recent WHO 2016 classification.

The largest series published so far by Cajaiba et al, reported the incidence of MiT-RCC to be approximately half of all pediatric RCCs.<sup>3</sup> Despite our conceivable registration bias, our SIOP-RTSG series

reveals a similar frequency (36/64) of MiT-RCC in the tested series. Such percentages need however to be interpreted with caution. RCC with TFE3 arrangements should reliably be detected using a combination of characteristic morphologic features, under expression of epithelial markers and nuclear TFE3 immunohistochemical expression. Cajaiba et al stated that although TFE3 overexpression by immunohistochemical staining for the diagnosis of MiT-RCC is highly specific, it needs to be carefully considered in the context of appropriate histologic and other immunophenotypic appearance.<sup>3,48</sup> Given the low numbers of pediatric MiT-RCC and the need for a combination of immunohistochemistry and molecular analysis, central review in centers providing these analyses is preferable. The most common histological subtypes in the group of patients not tested for TFE-translocations were papillary type RCC and clear cell RCC, which is in line with previously published pediatric RCC data using older classification systems.<sup>8,49,50</sup> Furthermore, while 26/208 patients with renal medullary carcinoma were reported by Cajaiba et al, we found only three cases.<sup>3</sup> The percentage of clear cell RCC (6.3%) in TFE-tested patients is in line with previously published results.<sup>3,9</sup> Last, in our series in the TFE untested group 15.8% of the pediatric RCCs remained unclassified. This might illustrate that TFE-testing enhances classification of difficult cases that occurred in the past.

In our cohort, the 5y EFS and 5y OS of MiT-RCC-positive patients were 64.3% and 86.2%, respectively, which appears to be lower in comparison to TFE-negative patients in the TFE-tested group. For the cohort in which translocation testing was performed, the patients with MiT-RCC accounted for the majority of metastatic (77.8%) and regionally advanced (78.6%) cases. This is in line with the previously mentioned increased risk of disseminated disease at presentation and a more aggressive course in case of MiT-RCC.<sup>11,51,52</sup> However, as TFE-testing was only feasible in a subset of this small pediatric RCC cohort, and registration may be biased, it is difficult to draw firm conclusions on the impact of positive TFE-testing on survival in our descriptive study. Furthermore, outcome of different histological subtypes could not correctly be interpreted given the small number of patients and potential shift in histological diagnoses due to TFE-testing.

Reported outcomes of pediatric RCC are variable, probably due to the small cohorts and lack of large prospective multicenter studies.<sup>9,13,53</sup> In our cohort, the estimated 5y EFS and 5y OS were 70.5% and 84.5%, respectively. The 5y OS is consistent with the range of the previous reported North-American and European studies that reported survival rates of 70% to 92%.<sup>6,9,10</sup> However, follow-up time in previous studies is highly variable, as well as whether the events registered for the included patients solely defined the occurrence of a relapse or death. Therefore, comparison of our EFS- and OS-rates with other studies is challenging.

Metastatic disease is associated with substantially lower survival. In previous studies, about 20% of children with RCC had been reported to present with distant metastases, which was associated with adverse outcome.<sup>1,6,12,15</sup> Our series showed an estimated 5y OS of 45.6% for patients with metastatic disease, whereas outcome for localized and regionally advanced disease, according to previous

results, is excellent.<sup>1,6,12</sup> Previous reports have suggested several other factors that influence survival in pediatric RCC, which included tumor size, pathologic stage, lymph node status, MiT-RCC and age.<sup>1,6,9,11,22</sup> We observed a decreased outcome in patients with N1M0 disease compared to patients with NOM0 disease. Remarkably, pediatric patients with regional lymph node invasion without distant metastases seem to have a better outcome compared to adult patients with comparable RCC disease status.<sup>1,5,9</sup> The relative few events in our cohort did not allow a proper multivariable analysis of potential prognostic factors.

Recently, the SIOP-RTSG UMBRELLA 2016 protocol has been launched. The study aims for full registration of all pediatric RCCs including germline genetics information, high quality TFE-testing, biobanking and development of tumor models for target identification and compound screening, in order to provide enhanced targeted treatment options for children with pediatric RCC in the future.

### ACKNOWLEDGMENTS

We are indebted to the national coordinating centers that provided us with missing data. We would like to acknowledge Prof Dr med I. Leuschner (now deceased) and Dr J. de Kraker (now deceased) for their leadership in the SIOP-RTSG and consequent contribution. There was no role for the Stichting Kinderen Kankervrij funding in the study design, in the collection, analysis, interpretation of data, in the writing of the report and in the decision to submit the paper for publication.

### CONFLICT OF INTEREST

The authors declare no potential conflict of interest.

### DATA AVAILABILITY STATEMENT

The data that support the findings of this study are available in the Supporting Information and from the International Society of Pediatric Oncology-Renal Tumor Study Group office following standard access procedures upon reasonable request.

### ETHICS STATEMENT

Informed consent from registration in the SIOP 93-01, SIOP 2001 (SIOP WT 2001 trial, EudraCT number: 2007-004591-39), and UK-IMPORT (London Bridge number: 12/LO/0101) studies had been obtained from parents of included pediatric patients prior to treatment, according to national law and regulations.

### ORCID

Justine N. van der Beek  <https://orcid.org/0000-0002-4798-8787>

Manfred Gessler  <https://orcid.org/0000-0002-7915-6045>

### REFERENCES

- Geller JI, Dome JS. Local lymph node involvement does not predict poor outcome in pediatric renal cell carcinoma. *Cancer*. 2004;101:1575-1583.
- Spreafico F, Collini P, Terenziani M, Marchiano A, Piva L. Renal cell carcinoma in children and adolescents. *Expert Rev Anticancer Ther*. 2010;10:1967-1978.
- Cajaiba MM, Dyer LM, Geller JI, et al. The classification of pediatric and young adult renal cell carcinomas registered on the children's oncology group (COG) protocol AREN03B2 after focused genetic testing. *Cancer*. 2018;124:3381-3389.
- Pastore G, Znaor A, Spreafico F, Graf N, Pritchard-Jones K, Steliarova-Foucher E. Malignant renal tumours incidence and survival in European children (1978-1997): report from the Automated Childhood Cancer Information System project. *Eur J Cancer*. 2006;42:2103-2114.
- Geller JI, Ehrlich PF, Cost NG, et al. Characterization of adolescent and pediatric renal cell carcinoma: a report from the Children's Oncology Group study AREN03B2. *Cancer*. 2015;121:2457-2464.
- Rialon KL, Gulack BC, Englum BR, Routh JC, Rice HE. Factors impacting survival in children with renal cell carcinoma. *J Pediatr Surg*. 2015;50:1014-1018.
- Freedman AL, Vates TS, Stewart T, Padiyar N, Perlmutter AD, Smith CA. Renal cell carcinoma in children: the Detroit experience. *J Urol*. 1996;155:1708-1710.
- Bruder E, Passera O, Harms D, et al. Morphologic and molecular characterization of renal cell carcinoma in children and young adults. *Am J Surg Pathol*. 2004;28:1117-1132.
- Selle B, Furtwangler R, Graf N, Kaatsch P, Bruder E, Leuschner I. Population-based study of renal cell carcinoma in children in Germany, 1980-2005: more frequently localized tumors and underlying disorders compared with adult counterparts. *Cancer*. 2006;107:2906-2914.
- Ramphal R, Pappo A, Zielenska M, Grant R, Ngan BY. Pediatric renal cell carcinoma: clinical, pathologic, and molecular abnormalities associated with the members of the mit transcription factor family. *Am J Clin Pathol*. 2006;126:349-364.
- Geller JI, Argani P, Adeniran A, et al. Translocation renal cell carcinoma: lack of negative impact due to lymph node spread. *Cancer*. 2008;112:1607-1616.
- Silberstein J, Grabowski J, Saltzstein SL, Kane CJ. Renal cell carcinoma in the pediatric population: results from the California Cancer Registry. *Pediatr Blood Cancer*. 2009;52:237-241.
- Cook A, Lorenzo AJ, Salle JL, et al. Pediatric renal cell carcinoma: single institution 25-year case series and initial experience with partial nephrectomy. *J Urol*. 2006;175:1456-1460.
- Indolfi P, Spreafico F, Collini P, et al. Metastatic renal cell carcinoma in children and adolescents: a 30-year unsuccessful story. *J Pediatr Hematol Oncol*. 2012;34:e277-e281.
- Indolfi P, Terenziani M, Casale F, et al. Renal cell carcinoma in children: a clinicopathologic study. *J Clin Oncol*. 2003;21:530-535.
- Eble JN, Sauter G, Epstein JI, Sesterhenn IA. *World Health Organization Classification of Tumours. Pathology and Genetics of Tumours of the Urinary System and Male Genital Organs*. Lyon: IARC Press; 2004.
- O'Toole KM, Brown M, Hoffmann P. Pathology of benign and malignant kidney tumors. *Urol Clin North Am*. 1993;20:193-205.
- Edge SB, Compton CC. The American Joint Committee on Cancer: the 7th edition of the AJCC cancer staging manual and the future of TNM. *Ann Surg Oncol*. 2010;17:1471-1474.
- Vujanic GM, Sandstedt B, Harms D, Kelsey A, Leuschner I, de Kraker J. Revised International Society of Paediatric Oncology (SIOP) working classification of renal tumors of childhood. *Med Pediatr Oncol*. 2002;38:79-82.
- Compton CC, Byrd DR, Garcia-Aguilar J, Kurtzman SH, Olawaiye A, Washington MK. *AJCC Cancer Staging Atlas*. 2nd ed. New York, NY: Springer; 2012.
- Uchiyama M, Iwafuchi M, Yagi M, et al. Treatment of childhood renal cell carcinoma with lymph node metastasis: two cases and a review of literature. *J Surg Oncol*. 2000;75:266-269.
- Akhavan A, Richards M, Shnorhavorian M, Goldin A, Gow K, Mergerian PA. Renal cell carcinoma in children, adolescents and

- young adults: a National Cancer Database study. *J Urol*. 2015;193:1336-1341.
23. Castellanos RD, Aron BS, Evans AT. Renal adenocarcinoma in children: incidence, therapy and prognosis. *J Urol*. 1974;111:534-537.
  24. Baek M, Jung JY, Kim JJ, Park KH, Ryu DS. Characteristics and clinical outcomes of renal cell carcinoma in children: a single center experience. *Int J Urol*. 2010;17:737-740.
  25. Rao Q, Chen JY, Wang JD, et al. Renal cell carcinoma in children and young adults: clinicopathological, immunohistochemical, and VHL gene analysis of 46 cases with follow-up. *Int J Surg Pathol*. 2011;19:170-179.
  26. Wu A, Kunju LP, Cheng L, Shah RB. Renal cell carcinoma in children and young adults: analysis of clinicopathological, immunohistochemical and molecular characteristics with an emphasis on the spectrum of Xp11.2 translocation-associated and unusual clear cell subtypes. *Histopathology*. 2008;53:533-544.
  27. Carlo MI, Mukherjee S, Mandelker D, et al. Prevalence of germline mutations in cancer susceptibility genes in patients with advanced renal cell carcinoma. *JAMA Oncol*. 2018;4:1228-1235.
  28. van der Beek JN, Geller JI, de Krijger RR, et al. Characteristics and outcome of children with renal cell carcinoma: a narrative review. *Cancers*. 2020;12:1776.
  29. Littooi AS, Sebire NJ, Olsen OE. Whole-tumor apparent diffusion coefficient measurements in nephroblastoma: can it identify blastemal predominance? *J Magn Reson Imaging*. 2017;45:1316-1324.
  30. Watson T, Oostveen M, Rogers H, Pritchard-Jones K, Olsen O. The role of imaging in the initial investigation of paediatric renal tumours. *Lancet Child Adolesc Health*. 2020;4:232-241.
  31. van den Heuvel-Eibrink MM, Hol JA, Pritchard-Jones K, et al. Position paper: rationale for the treatment of Wilms tumour in the UMBRELLA SIOP-RTSG 2016 protocol. *Nat Rev Urol*. 2017;14:743-752.
  32. Littooi AS, Nikkels PG, Hulsbergen-van de Kaa CA, van de Ven CP, van den Heuvel-Eibrink MM, Olsen OE. Apparent diffusion coefficient as it relates to histopathology findings in post-chemotherapy nephroblastoma: a feasibility study. *Pediatr Radiol*. 2017;47:1608-1614.
  33. Cost NG, Geller JI, DeFoor WR Jr, Wagner LM, Noh PH. A robotic-assisted laparoscopic approach for pediatric renal cell carcinoma allows for both nephron-sparing surgery and extended lymph node dissection. *J Pediatr Surg*. 2012;47:1946-1950.
  34. Geller JI, Cost NG, Chi YY, et al. A prospective study of pediatric renal cell carcinoma: a report from the Children's Oncology Group study AREN0321. *J Clin Oncol*. 2018;36:10516.
  35. Terrone C, Guercio S, De Luca S, et al. The number of lymph nodes examined and staging accuracy in renal cell carcinoma. *BJU Int*. 2003;91:37-40.
  36. Johnsen JA, Hellsten S. Lymphatogenous spread of renal cell carcinoma: an autopsy study. *J Urol*. 1997;157:450-453.
  37. Ambalavanan M, Geller JI. Treatment of advanced pediatric renal cell carcinoma. *Pediatr Blood Cancer*. 2019;66:e27766.
  38. Carcao MD, Taylor GP, Greenberg ML, et al. Renal-cell carcinoma in children: a different disorder from its adult counterpart? *Med Pediatr Oncol*. 1998;31:153-158.
  39. Choueiri TK, Mosquera JM, Hirsch MS. A case of adult metastatic Xp11 translocation renal cell carcinoma treated successfully with sunitinib. *Clin Genitourin Cancer*. 2009;7:E93-E94.
  40. Malouf GG, Camparo P, Oudard S, et al. Targeted agents in metastatic Xp11 translocation/TFE3 gene fusion renal cell carcinoma (RCC): a report from the Juvenile RCC Network. *Ann Oncol*. 2010;21:1834-1838.
  41. Chowdhury T, Pritchard-Jones K, Sebire NJ, et al. Persistent complete response after single-agent sunitinib treatment in a case of TFE translocation positive relapsed metastatic pediatric renal cell carcinoma. *J Pediatr Hematol Oncol*. 2013;35:e1-e3.
  42. Calandrini C, Schutgens F, Oka R, et al. An organoid biobank for childhood kidney cancers that captures disease and tissue heterogeneity. *Nat Commun*. 2020;11:1310.
  43. Geller JI, Fox E, Turpin BK, et al. A study of axitinib, a VEGF receptor tyrosine kinase inhibitor, in children and adolescents with recurrent or refractory solid tumors: a Children's Oncology Group phase 1 and pilot consortium trial (ADVL1315). *Cancer*. 2018;124:4548-4555.
  44. Motzer RJ, Penkov K, Haanen J, et al. Avelumab plus axitinib versus sunitinib for advanced renal-cell carcinoma. *N Engl J Med*. 2019;380:1103-1115.
  45. Rini BI, Plimack ER, Stus V, et al. KEYNOTE-426 investigators. Pembrolizumab plus axitinib versus sunitinib for advanced renal-cell carcinoma. *N Engl J Med*. 2019;380:1116-1127.
  46. Choueiri TK, Hessel C, Halabi S, et al. Cabozantinib versus sunitinib as initial therapy for metastatic renal cell carcinoma of intermediate or poor risk (Alliance A031203 CABOSUN randomised trial): progression-free survival by independent review and overall survival update. *Eur J Cancer*. 2018;94:115-125.
  47. Moch H, Cubilla AL, Humphrey PA, Reuter VE, Ulbright TM. The 2016 WHO classification of tumours of the urinary system and male genital organs-part a: renal, penile, and testicular tumours. *Eur Urol*. 2016;70:93-105.
  48. Argani P, Lal P, Hutchinson B, Lui MY, Reuter VE, Ladanyi M. Aberrant nuclear immunoreactivity for TFE3 in neoplasms with TFE3 gene fusions: a sensitive and specific immunohistochemical assay. *Am J Surg Pathol*. 2003;27:750-761.
  49. Renshaw AA, Granter SR, Fletcher JA, Kozakewich HP, Corless CL, Perez-Atayde AR. Renal cell carcinomas in children and young adults: increased incidence of papillary architecture and unique subtypes. *Am J Surg Pathol*. 1999;23:795-802.
  50. Sebire NJ, Vujanac GM. Paediatric renal tumours: recent developments, new entities and pathological features. *Histopathology*. 2009;54:516-528.
  51. Argani P, Antonescu CR, Illei PB, et al. Primary renal neoplasms with the ASPL-TFE3 gene fusion of alveolar soft part sarcoma: a distinctive tumor entity previously included among renal cell carcinomas of children and adolescents. *Am J Pathol*. 2001;159:179-192.
  52. Sukov WR, Hodge JC, Lohse CM, et al. TFE3 rearrangements in adult renal cell carcinoma: clinical and pathologic features with outcome in a large series of consecutively treated patients. *Am J Surg Pathol*. 2012;36:663-670.
  53. Aronson DC, Medary I, Finlay JL, Herr HW, Exelby PR, La Quaglia MP. Renal cell carcinoma in childhood and adolescence: a retrospective survey for prognostic factors in 22 cases. *J Pediatr Surg*. 1996;31:183-186.

## SUPPORTING INFORMATION

Additional supporting information may be found online in the Supporting Information section at the end of this article.

**How to cite this article:** van der Beek JN, Hol JA, Coulomb-l'Hermine A, et al. Characteristics and outcome of pediatric renal cell carcinoma patients registered in the International Society of Pediatric Oncology (SIOP) 93-01, 2001 and UK-IMPORT database: A report of the SIOP-Renal Tumor Study Group. *Int. J. Cancer*. 2021;148:2724–2735. <https://doi.org/10.1002/ijc.33476>