



The perfect ileal pouch–anal anastomosis

N. Ecker¹ · A.-C. Woywod² · K.-W. Ecker^{3,4,5}

Received: 12 August 2022 / Accepted: 1 September 2022
© The Author(s) 2022

In ileal pouch–anal anastomosis, pitfalls may result from inappropriate anastomotic height, rectal cuff, sphincter damage, residual rectal mucosa, dog-ears in double-stapler technique (persistent inflammation, risk of malignancy), and temporary fecal diversion. Most surgical techniques either overvalue or neglect particular aspects (Figs. 1, 2, 3, 4, 5, 6, 7, 8, 9).

Exact digital height determination, additional purse-string suture in double-stapler technique, and transanal temporary decompression by means of an ileostomy catheter are recommended to avoid all pitfalls and therefore to produce a "perfect" anastomosis in a standardized way.

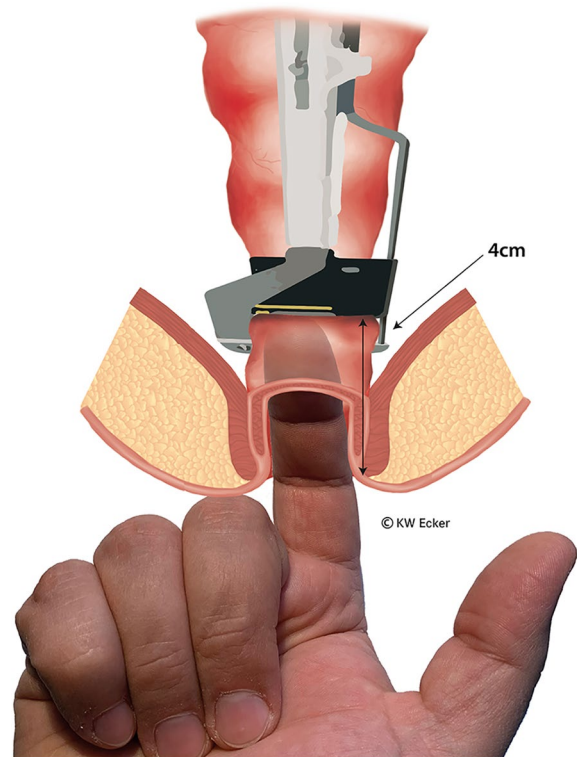


Fig. 1 Determination of the height of the rectal resection. The rectum is ideally resected at a height identified when the tip of the index finger is inserted transanally up to the second flexural crease and just feels the 30 mm linear stapler. This height of approximately 4 cm from the anocutaneous junction will be reduced by the subsequent steps

✉ K.-W. Ecker
karl-wilhelm.ecker@gmx.de

¹ Forstmeisterweg 65, 23564 Lübeck, Germany

² "Dr. Nölke," Königstraße 22, 25348 Glückstadt, Germany

³ Department of General, Visceral, Vascular, and Pediatric Surgery, University of Saarland, Homburg, Saar, Germany

⁴ Emeritus Director of the Surgical Department, MediClin Müritzklinikum, Weinbergstraße 19, 17192 Waren, Germany

⁵ Tannenweg 1, 22889 Tangstedt, Germany

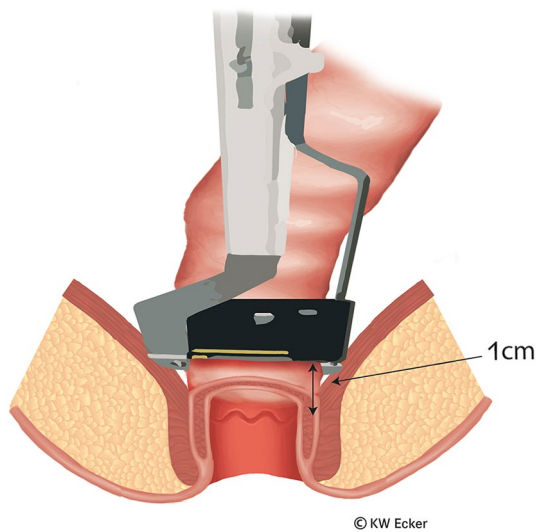


Fig. 2 Definitive positioning of the linear stapler. After moving the stapler slightly distally, it is closed and fired so that the rectum can be easily resected with the scalpel above the closed device. The staple suture line is then approximately 1 cm above the dentate line

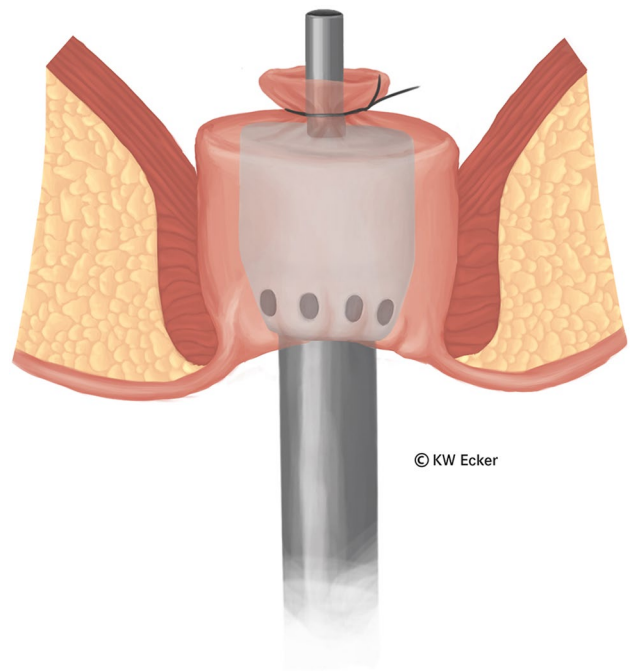


Fig. 4 Knotting the modified Asao suture. After the suture material has been carefully tightened, the ends are knotted. This incorporates the whole linear stapler line as well as all excess tissue centrally around the guide mandrel

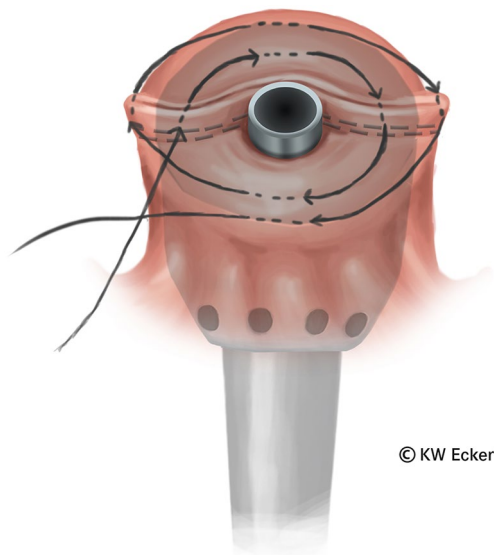
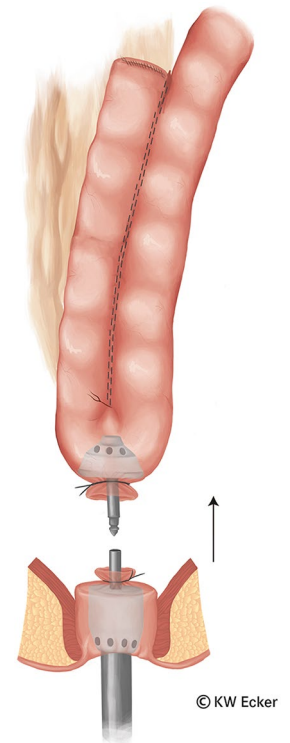


Fig. 3 Stitching a modified Asao suture. After the head of the largest possible (28–32 mm) circular stapler has been precisely positioned transanally, a purse-string suture is stitched in a double spiral. In this process, the lateral ends of the staple suture (dogears) are deeply and securely incorporated in the outer helix

Fig. 5 Connecting the circular stapler. The components of the circular stapler are now articulated together. Since the rectal stump is securely closed by the modified Asao suture, the pelvic floor can be pushed cranially by a few centimeters without risk, making it easier to reach the J-pouch with the knotted counterpressure plate



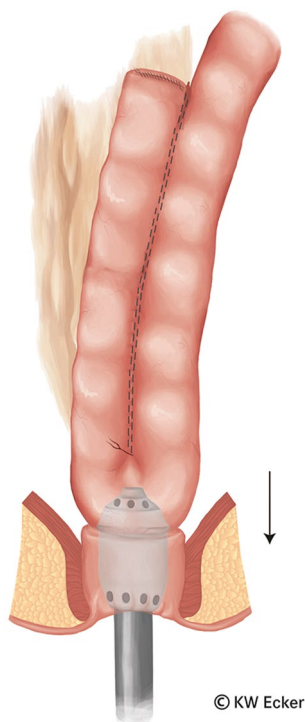


Fig. 6 Firing the circular stapler. After the assembled device has been closed, the tension on the rectal stump is reduced before firing, so that no tension exists on the subsequent anastomosis

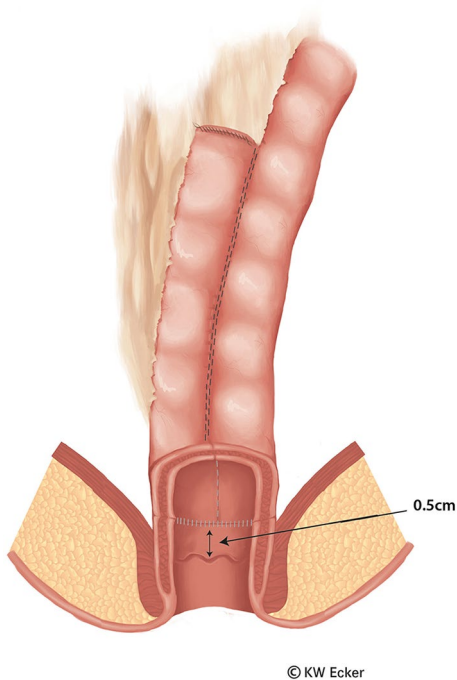


Fig. 7 Longitudinal section through the completed ileal pouch–anal anastomosis. It is clear to see that this is a clean circular anastomosis without any dogears. This means that the rectal mucosa is practically totally removed, except for a margin of only a few millimeters in the region of the transition zone. The preservation of this tissue guarantees the anal sensory system, which is important for proper continence

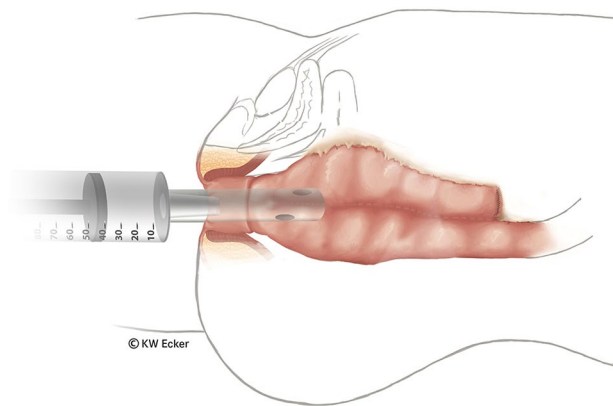


Fig. 8 Bubble test. After completion of the anastomosis, a soft ileostomy catheter is inserted transanally and a bubble test is performed. If air bubbles rise in the water-filled pelvis, the anastomosis is inspected with a proctologic retractor and any leaks in the anastomosis line are sutured manually

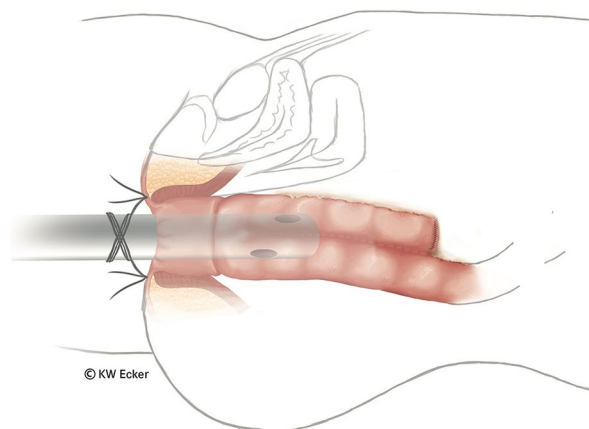


Fig. 9 Temporary transanal decompression. The soft ileostomy catheter remains in place for approximately 7 days as a substitute for a defunctioning ileostomy. It is sutured to the perianal skin with two stitches to prevent dislocation. Postoperatively, the ileostomy catheter should be irrigated regularly to ensure patency. It then relieves pressure on the pouch and anastomotic sutures during the first few days and protects the vulnerable anoderm during the initial postoperative period. As the bowel content thickens, the ileostomy catheter is removed and continence training begins

Author contributions This work is part of the dissertation of A-CW. All authors contributed to the paper conception and design: A-CW generated the images with special graphic software. NKJE wrote the first draft of the manuscript. K-WE developed the operative technique and revised the manuscript for important intellectual content. All authors commented on previous versions of the manuscript. All authors read and approved the final manuscript.

Funding Open Access funding enabled and organized by Projekt DEAL.

Availability of data and materials The data and all materials used are secured digitally by the corresponding author.

Code availability No code available.

Declarations

Conflict of interest There is no conflict of interest/competing interests of/for each author.

Ethical approval No approval of ethics required.

Consent to participate Not applicable.

Consent for publication Not applicable.

Open Access This article is licensed under a Creative Commons Attribution 4.0 International License, which permits use, sharing, adaptation, distribution and reproduction in any medium or format, as long as you give appropriate credit to the original author(s) and the source, provide a link to the Creative Commons licence, and indicate if changes were made. The images or other third party material in this article are

included in the article's Creative Commons licence, unless indicated otherwise in a credit line to the material. If material is not included in the article's Creative Commons licence and your intended use is not permitted by statutory regulation or exceeds the permitted use, you will need to obtain permission directly from the copyright holder. To view a copy of this licence, visit <http://creativecommons.org/licenses/by/4.0/>.

References

Ecker NKJ, Woywod AC, Ecker KW. Ileal pouch-anal anastomosis – a personal experience reevaluating complications, pouch survival, and quality of life. *coloproctology* 2021; 43:352–362; <https://doi.org/10.1007/s00053-021-00534-4>

Publisher's Note Springer Nature remains neutral with regard to jurisdictional claims in published maps and institutional affiliations.